

Case Study Examining the Efficacy of Continuous Topical Oxygen Therapy in Managing Chronic Ischemic Wounds Associated with Buerger's Disease

Dr. Joseph Larsen, DPM, DABFAS, Chair of Podiatry Optum Podiatry, United Health Group, NY | Nancy Stahulak, Vice President Sales & Marketing, NATROX® Wound Care

Introduction

Buerger's disease, (thromboangiitis obliterans), is a rare, non-atherosclerotic, segmental inflammatory vasculitis that primarily affects small- and medium-sized arteries and veins of the arms and legs impacting blood flow. The disease is typically found in the lower extremities, with skin ulceration and gangrene of the digits common, with pain being very intense¹. The disease typically presents with distal extremity ischemia; common for the foot as an early site of involvement; often manifesting as digital ulceration, claudication, rest pain, or gangrene.

In the US, current estimations on prevalence are 12.6 - 20 cases per 100,000 population².

Patient History and Treatment Plan

A 49 y/o male with Buerger's disease presented with a painful, non-healing ischemic foot ulcer complicated by osteomyelitis on the left hallux. The ulcer had a necrotic and gangrenous tissue center. After two months of standard of care (SOC) the wound measured 2.0 cm X 1.8 cm with a depth of 0.3 cm and was located on distal top left hallux.

The patient's medical history included high cholesterol and radiculopathy, and he was a former smoker. Medications included Gabapentin and Simvastatin. On examination, the left side demonstrated a nonpalpable pulse with an ankle-brachial index (ABI) of 0.72 and flattened digital waveforms. The patient reported constant pain rated at 10 out of 10.

The patient was seen by a vascular surgeon and had an angiogram and angioplasty of the left lower extremity. The wound treatment plan included a small, wearable, Continuous Topical Oxygen Therapy / Continuous Diffusion of Oxygen (cTOT / CDO) device. This therapy was initiated alongside an off-weighting shoe, collagen dressings, oral Bactrim, and anticoagulant medication. This treatment plan was supported with ongoing vascular and infectious disease consultations.

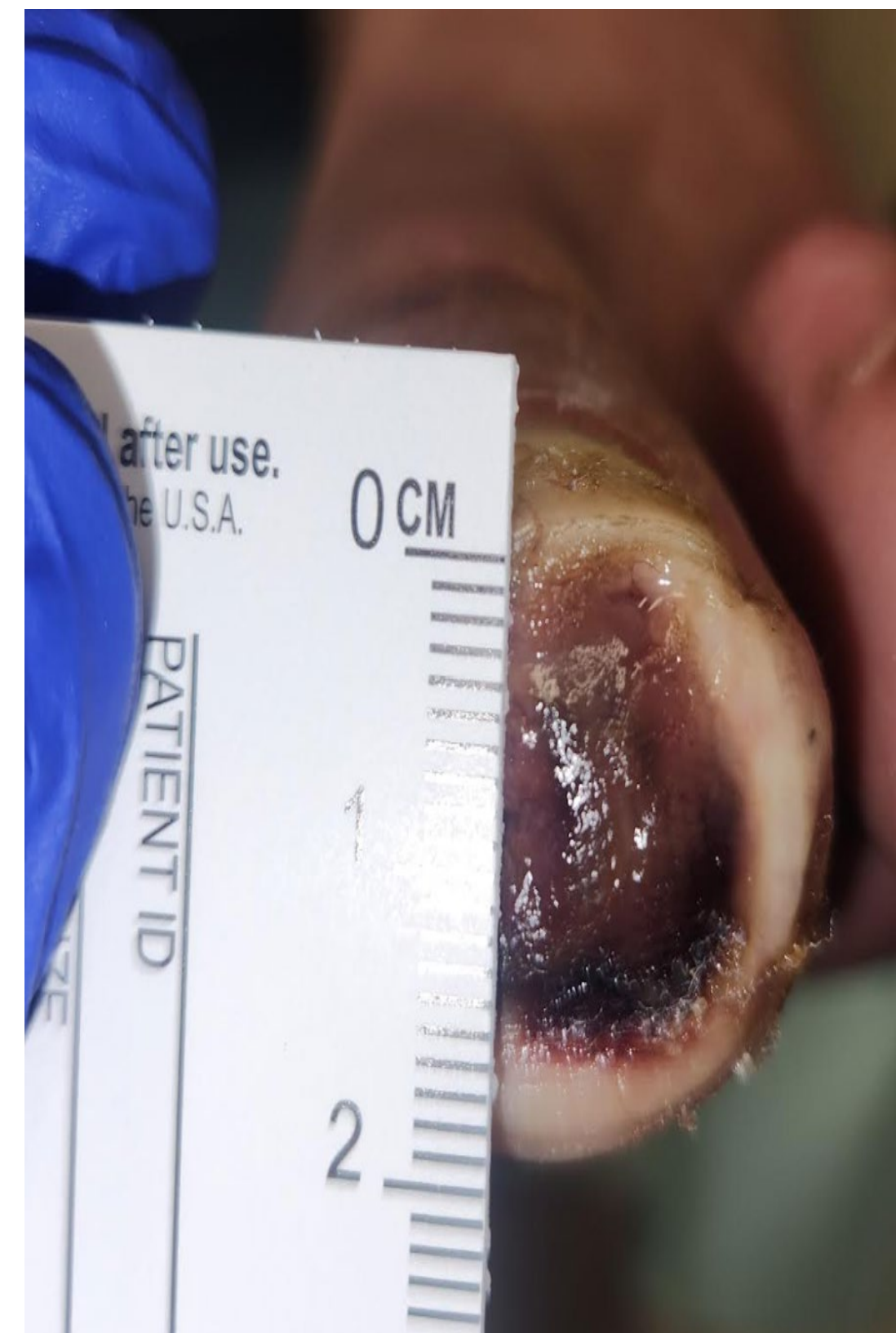References

1. Buerger's Disease. John Hopkins Vasculitis Center, 2025
2. Qaja E, Muco E, Hashmi MF. Buerger Disease. [Updated 2023 Feb 19]. In: StatPearls [Internet]. Treasure Island (FL): StatPearls Publishing; 2025 Jan- Available from: <https://www.ncbi.nlm.nih.gov/books/NBK430858/>
3. Jebrail, W. et al. *J Wound Care* 31, 4–11 (2022)
4. Chen, P. et al. IWGDF Guidelines on Interventions to Enhance Healing of Foot Ulcers in People with Diabetes. www.iwgdfguidelines.org (2023)
5. Lavery, L. A. et al. *Wound Repair and Regeneration* (2023)
6. American Diabetes Association Professional Practice Committee. (2026) 12. Retinopathy, Neuropathy, and Footcare: Standards of Care in Diabetes-2026. *Diabetes Care*, 49(Suppl 1):S268-S72.

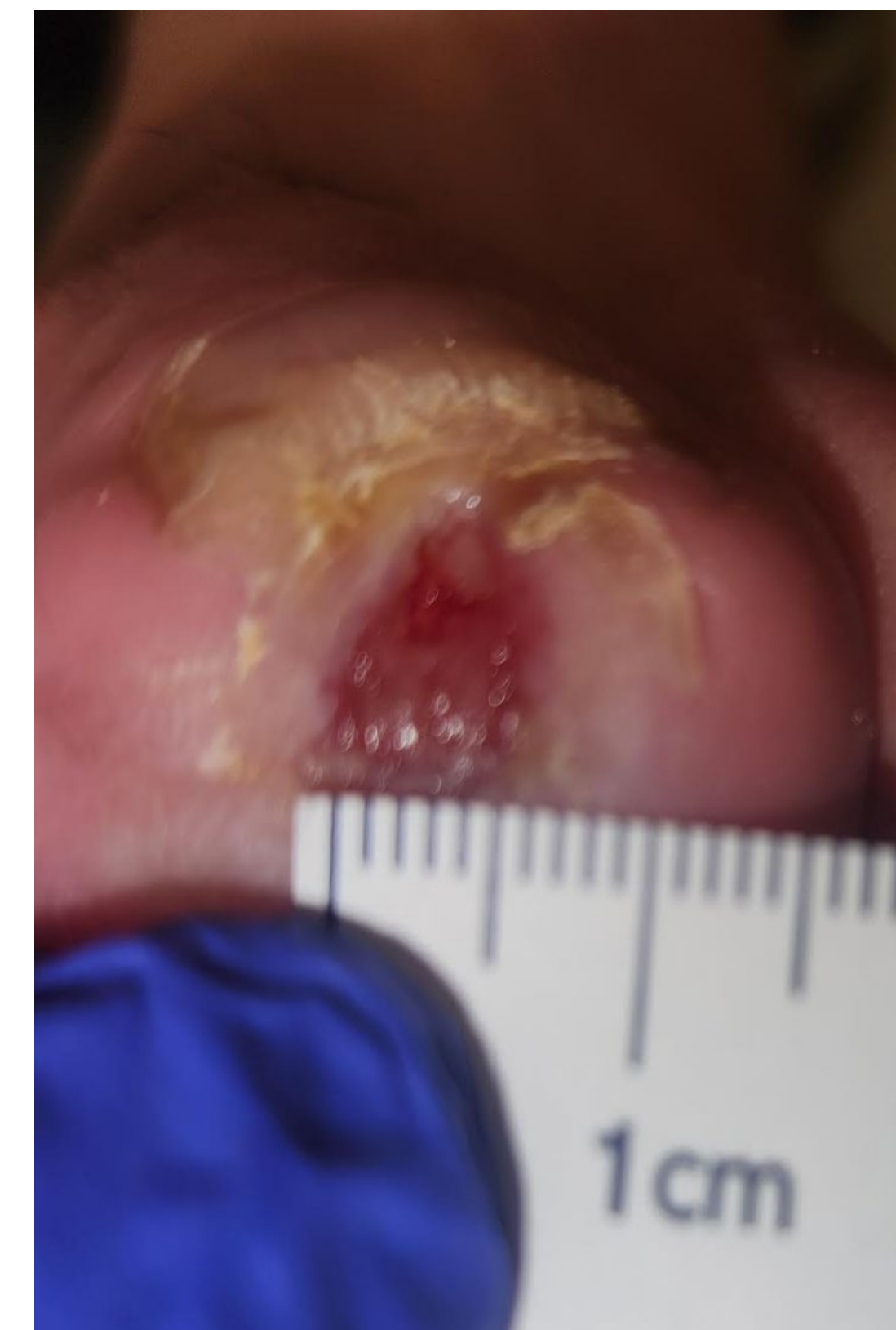
Results

Osteomyelitis was successfully treated with antibiotics. The ulcer achieved complete closure within five months of the initial presentation through the use of advanced dressings and cTOT / CDO therapy. Pain progressively decreased throughout the healing process. A coordinated, multidisciplinary approach combined with CDO therapy resulted in wound closure and ultimately avoided amputation.

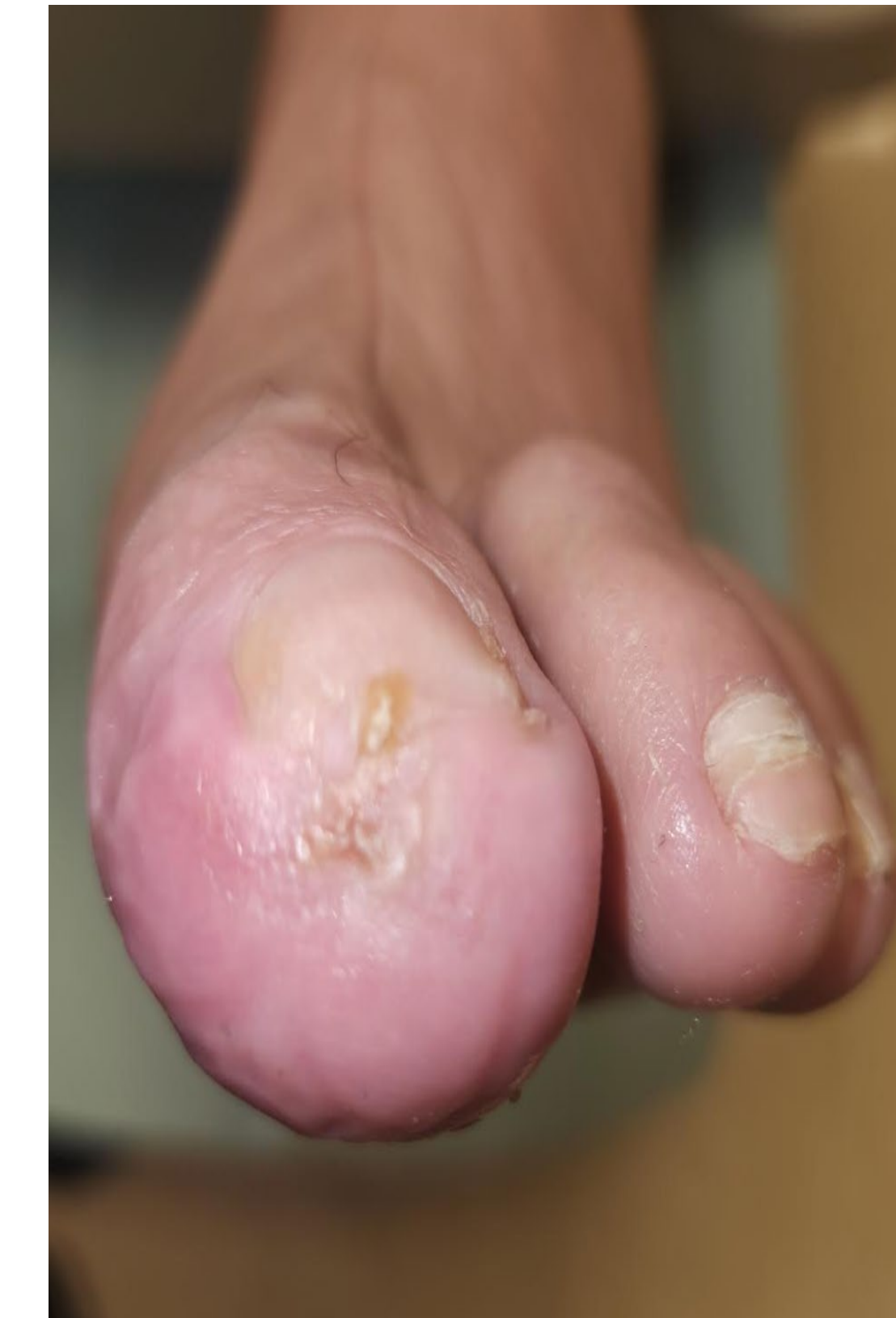Wound at initial
NATROX® O₂
application



18 weeks after
NATROX® O₂
application



22 weeks after
NATROX® O₂
application -
wound closed



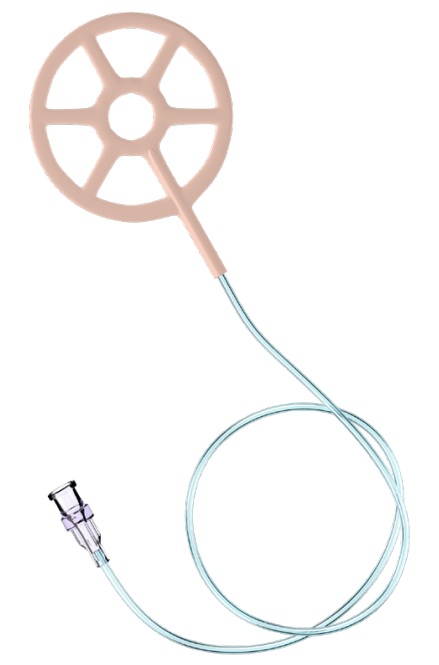
Discussion

Healing and pain reduction outcomes observed in this patient treated with cTOT / CDO are consistent with those reported in broader clinical studies, including randomized control trials and meta-analyses providing level 1 evidence. These results reinforce the efficacy of the device as a non-invasive therapy in managing chronic ischemic wounds such as those seen with Buerger's disease.

Given the well-documented challenges of wound healing in patients with compromised perfusion, such as those with thromboangiitis obliterans, the ability of cTOT to constantly deliver topical oxygen directly to the wound bed, addresses the problem of non-healing wounds due to hypoxia and can help with wound pain reduction³. This case study further highlights cTOT's / CDO's potential as a critical role in limb preservation improved quality of life, and reduction of major amputations in high-risk populations.

Topical Oxygen Therapy use is endorsed and recommended by international expert guidance including the IWGDF, WHS and the ADA^{4,5,6}.

Continuous Topical Oxygen (cTOT) Device



NATROX® O₂ Oxygen Generator (OG)

- Simple-to-use, battery-operated device – delivers continuous oxygen to the wound bed at a flow rate of 11ml / hr.
- Rechargeable batteries – One is in use while the other is charging
- Wearable – Patients can remain mobile while receiving therapy
- Lightweight and discreet – Device can be carried in a pocket
- Silent – no alarms that would disturb sleep

NATROX® O₂ Oxygen Delivery System (ODS)

- Sterile, single-use wound interface oxygen delivery system
- Soft and pliable – Easily conforms to the wound's anatomical location
- Used as an adjunct to current standard of care wound management options on formulary, including compression and TCC
- "Wheel" like design optimizes the flow and diffusion of oxygen across the wound bed while allowing free passage of wound exudate into the secondary dressing
- Connects to the OG via a twist-and-lock attachment

Contact Information

Joseph Larsen, DPM, DABFAS
Chair of Podiatry, Optum Podiatry
United Health Group
jlarsen@prohealthcare.com