

Evaluating the dispersion and residuum of a novel pure hypochlorous acid preserved antimicrobial wound gel* on intact skin



Laura Swoboda DNP (Carthage College- Kenosha, WI; Skin Gurus- Milwaukee, WI)

Purpose: This pilot study investigates the absorptive properties and qualities of a novel antimicrobial gel on intact human skin.

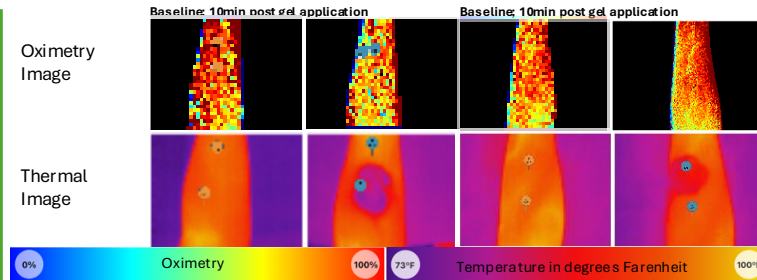
Introduction: Current topical wound care treatments often leave a residue or require prolonged drying times, which can negatively impact patient comfort, aesthetic perception, use, and adherence.

This study aimed to assess the dispersion & product residuum on intact skin of a new skin & wound antimicrobial gel* hypothesizing that its unique formulation with limited ingredients allows for swift dermal dispersion without leaving a sticky or visible cast or macerating the skin.

A key objective is to provide preliminary data supporting its potential use in a broader range of clinical applications where rapid clinical effect and subsequent dispersion is beneficial such as incontinence associated dermatitis, intertrigo, and in other clinical environments.

Methods: A single-center, small-cohort study was conducted on healthy adult volunteers (n=25). The antimicrobial hydrogel was applied to a standardized 2x2 cm area on the volar forearm. The post-application dispersion process was analyzed utilizing the Mimosa Pro™ digital imaging system to ensure consistency and high-quality data including the contralateral limb volar surface. Multi-spectral tissue interrogation collected tissue oximetry, temperature, and a digital image followed by assessment via handheld low power point of care microscopy. The antimicrobial hydrogel was maintained at ambient room temperature and humidity conditions for 3 months prior to use. Product was agitated for 10 seconds manually prior to use, and first 5cc expressed was discarded.

Image collection captured baseline images of the skin. Imaging room temperature 81 degrees Fahrenheit; Imaging room humidity 39%. Sequential images were then taken at 5-minute intervals for 20 minutes to visually assess the rate of dispersion and the presence of any residuum. A quantitative score was later assigned by a blinded specialist based on the visual evidence. Additionally, a subjective Likert questionnaire was administered to gauge the sensation of stickiness. (Both 1-5 Likert style assessment scales with 1 being no negative stimuli and 5 being obvious negative stimuli).

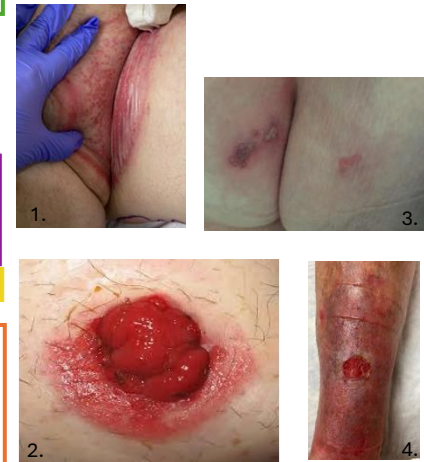

Results:

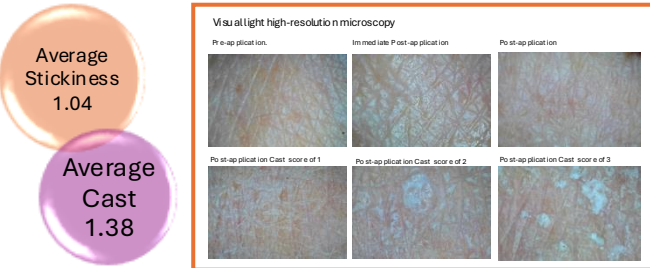- rapid dissipation and dispersion: majority of gel visibly dissipated within the assessment period of 20 minutes in all applications.
- average reported cast score found of 1.38
- average stickiness reported was 1.04
- 5 minute average tissue temperature decrease of 4-10 degrees Fahrenheit
- generalized tissue cooling within and outside of assessment window
- high-resolution, multi spectral images confirm visual observations, demonstrating the skin's surface returning to pre-application appearance with minimal to no residuum.
- no maceration was noted.

Discussion: This pilot study demonstrates the remarkable dissipation qualities of the novel hypochlorous acid-preserved gel. Its rapid dissipation and non-adhesive finish suggest significant advantages over other hydrophilic polymer loaded thick antimicrobial gel type topical preparations. *The observed properties of this new gel could enhance patient compliance and expand its utility beyond typical wound care.* A reduction in dermal skin temperature of approximately 4-10 degrees was noted via thermography. In addition, the positive stimuli of a localized cooling sensation noted via thermography was reported verbally, and did NOT contribute to microvascular vasoconstriction over that observed during gross cutaneous cooling with generalized exposure as noted with NIRs. An average cast score of ~1.5 was expected, indicating minimal to no residue, and the gel performed as expected at 1.38. Future, larger-scale studies are warranted to further explore its efficacy and potential for widespread application, though these preliminary results show positive cutaneous dispersion characteristics with minimal residue or casting.

Visual Light Images demonstrating where rapid dispersion of HClO gel coupled with minimal casting are beneficial and alternative treatment vehicles (oils, creams, heavy gels) impact patient comfort, aesthetic perception, use, or adherence:



Case 1: Incontinence associated dermatitis of the left inguinal fold in a 64 year old male with long-term diabetes.
Case 2: Peri-stomal dermatitis of loop colostomy impacting pouch adherence.
Case 3: Peri-anal herpes / herpetic whitlow of the buttock
Case 4: Contact dermatitis of the peri-wound, prior to HClO treatment



*1 = no cast/stickiness

* Wash gel - Vashe antimicrobial wound gel, Urgo Medical Group, Paris, France.

1. Tzen YT, Delmore B, M Bogie K, Sonenblum SE, Newton D, Vargo D, Ronin J, Hester A, Gillespie C, Tescher A, Jyer V, Brienza D. State-of-the-Art Review of Current Technology in Pressure Injury Early Detection. *Adv Skin Wound Care*. 2025 Nov-Dec 01;38(10):E128-E137. doi: 10.1097/ASM.0000000000000358. Epub 2025 Oct 14. PMID: 41085249; PMCID: PMC12610902.
 2. Czapalló A, Ortega-Loayza AG, Kozendorfer H, James F, Dotson P, Khimchenko A, Driver VR, Sonenblum SE. Advancing chronic wound care with near-infrared spectroscopy imaging: clinical applications, measurement parameters, and insights into healing dynamics. *Wounds*. 2025 Oct;37(10):384-392. PMID: 41270199.

References