

The Evaluation of a Combined Methylidene Malonate Tissue Adhesive and Light Switchable Adhesive Film for a Post-Operative Incisional Dressing

Thomas Davenport MD, Steve Stavrides PA, Mia Perkell BS | New York Surgical Plastic Group

STUDY OBJECTIVE

The study reports on the first clinical experience combining Methylidene Malonate (MM) Tissue Adhesive and Light Switchable Adhesive Film (LSAFD) as a post-operative incisional dressing.

INTRODUCTION

Cyanoacrylate tissue adhesives have become a standard post-operative dressing, and the use of these products has shown improved surgical outcomes. However, cyanoacrylate breakdown byproducts can result in a high incidence of dermatitis^{1,2}. A new tissue adhesive formulation utilizing methylidene malonate has similar closure qualities to cyanoacrylates and low incidence of skin reactions³.

BACKGROUND

2-octyl-cyanoacrylate-mesh-systems emit formaldehyde at levels exceeding sensitization and inhalation thresholds, raising concern for dermal and respiratory exposure, particularly in sensitized individuals⁴. Prior sensitization from adhesives such as nail, eyelash or super glues may heighten risk⁴. Film dressings are commonly applied for additional wound protection, but their removal may result in inflammation or medical adhesive-related skin injury (MARS), with a reported prevalence of 16% and an average treatment cost of \$88.50 per injury⁵. Removal can also be painful for the patient.

SOLUTION

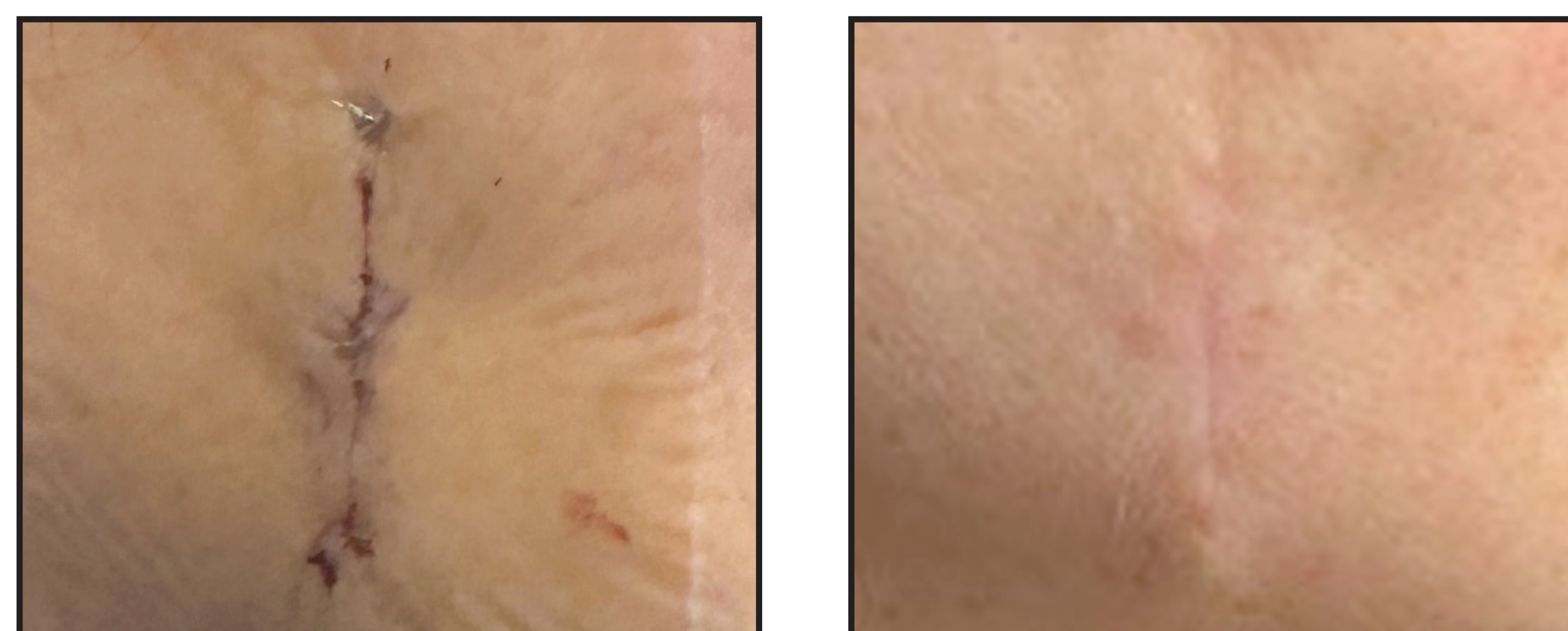
The introduction of a light-switchable polyurethane adhesive enables atraumatic removal by reducing adhesive strength upon exposure to a specific wavelength of light, reducing both MARS risk and patient discomfort^{6,7}. By using the MM tissue adhesive and the LSAFD together, the incision can be sealed to protect the site, act as a bacterial barrier, and reinforce the closure.

This case series evaluates the combined use of the methylidene malonate tissue glue and the light-switchable film dressings (LSAFD) on a series of patients following primary wound closure with subcuticular sutures.

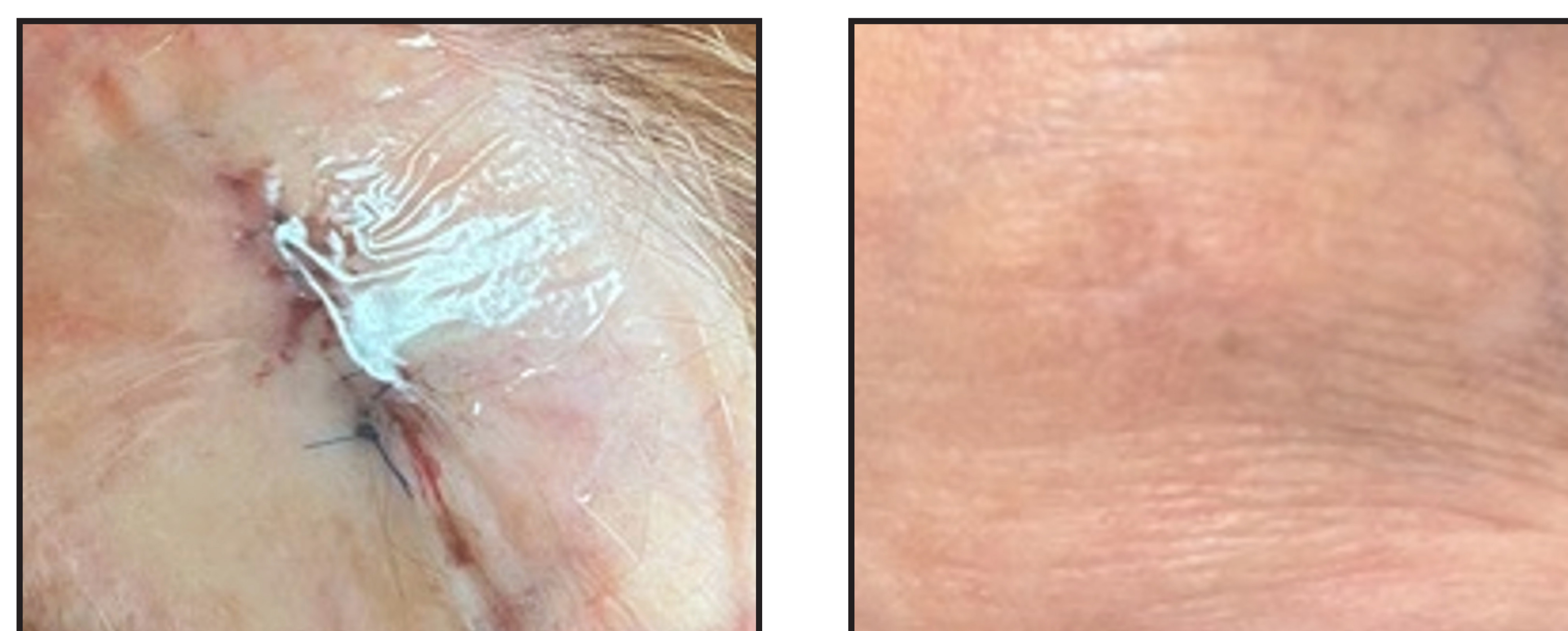
METHODS

This case series describes the management of 15 patients with MM tissue glue for skin closure and the use of LSAFD to protect the incision site. MM glue followed by LSAFD were applied at the time of closure, and the patients were told they could wash the area without restriction. Incisions were from various surgical etiologies and body parts. At seven days the patient returned for suture removal and wound evaluation.

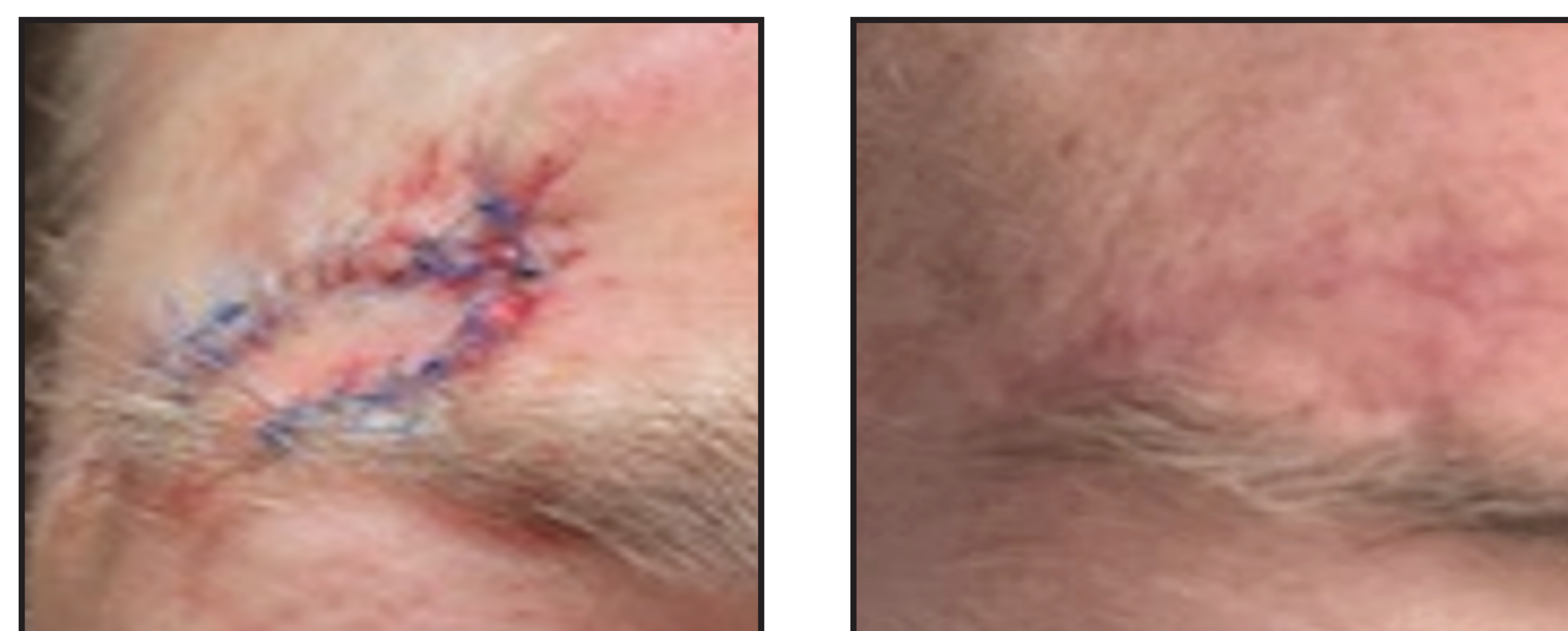
Case 1



Case 2



Case 3



RESULTS

- At seven-day follow-up, all patients (15/15) demonstrated successful wound closure without signs of inflammation, erythema, or dermatitis.
- LSAFD removal was painless and effectively removed residual tissue glue.
- All patients reported no difficulty with washing the area and there were no short term infections or wound dehiscence.
- All incisions showed no dermatitis and no infection at long term follow up occurring between 1 and 3 months.

DISCUSSION

This pilot study assessed short term inflammation and patient experience. The combined use of methylidene malonate tissue adhesive and the light switchable adhesive film as a post-operative incisional dressing resulted in uncomplicated wound healing, no dermatitis, no infection, and improved patient experience. The film dressing protected the incisional site for 7 days, providing peace of mind and allowing activities of daily living. At long-term follow up, incisions healed with good cosmetic outcomes.

CONCLUSION

This case series demonstrates the clinical outcomes of healed surgical wounds following the combined use of methylidene malonate tissue adhesive the light switchable adhesive film dressing. In 15 patients, all wounds healed without complication.

References:

1. Nigro et al, *Plastic and Reconstructive Surgery*, 145(1):p 32-37 2020
2. Park et al. *Scientific Reports*, 11:23762 2021
3. *OptMed Clinical Study Report: PD-100-002/20140409*
4. Daniel S. Rouhani et al, *Contact Dermatitis*, 2026; 0:1-10
5. Wang et al. *J. Tiss. Viability* 2025 33(4) 960-967
6. Cayce et al. *ABA* 2025
7. Cayce et al. *SAWC Spring* 2025

This work is supported by DeRoyal Industries and Dr. Davenport is a paid consultant of DeRoyal Industries, Inc.