

# Biological Graft Use in the Treatment of Refractory Hidradenitis Suppurativa

Colleen McGarvey<sup>1</sup>, Emma Amjad<sup>1</sup>, Payton Millman<sup>1</sup>, Dr. Jessica Wise<sup>2</sup>, Dr. Matthew Johnson<sup>2</sup>, Dr. Melanie Hyte<sup>1</sup>

<sup>1</sup>Edward Via College of Osteopathic Medicine - Auburn

<sup>2</sup>HCA Destin - Fort Walton Beach

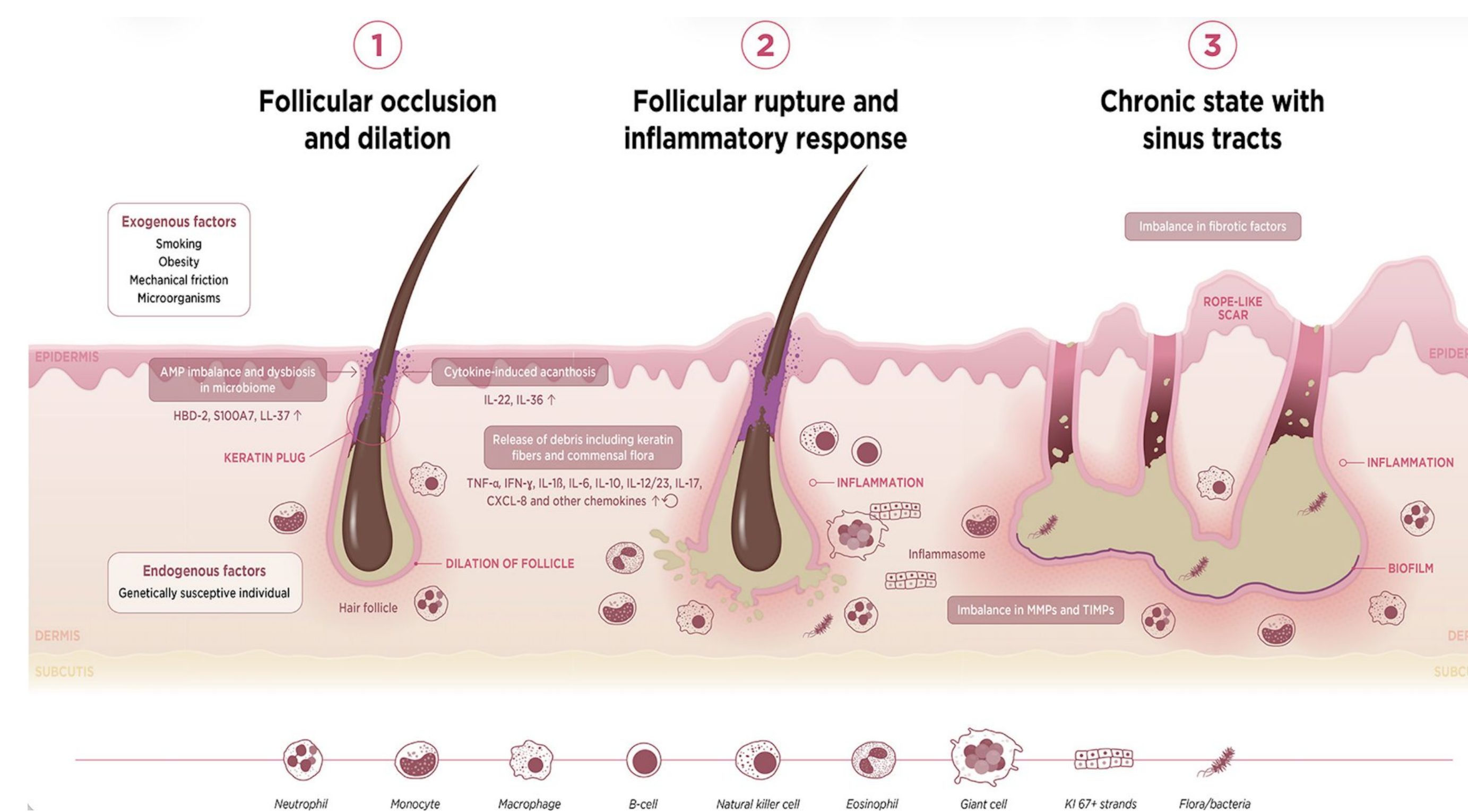
## BACKGROUND

- Hidradenitis suppurativa (HS), or acne inversa, is a chronic inflammatory disorder of the hair follicle.
- Characterized by recurrent nodules, abscesses, draining sinus tracts, and progressive scarring.
- Typically affects apocrine gland-bearing areas such as the axillae, groin, inner thighs, and buttocks.
- Diagnosis is clinical based on characteristic lesions, location, and recurrence.
- Disease severity is commonly classified using the Hurley staging system.
- First-line management includes lifestyle modification (smoking cessation, weight loss) and medical therapy such as antibiotics or anti-inflammatory agents.
- Biologic therapy may be used for moderate to severe or refractory disease.
- Surgical intervention is often required for advanced disease and may be potentially curative.

## CASE

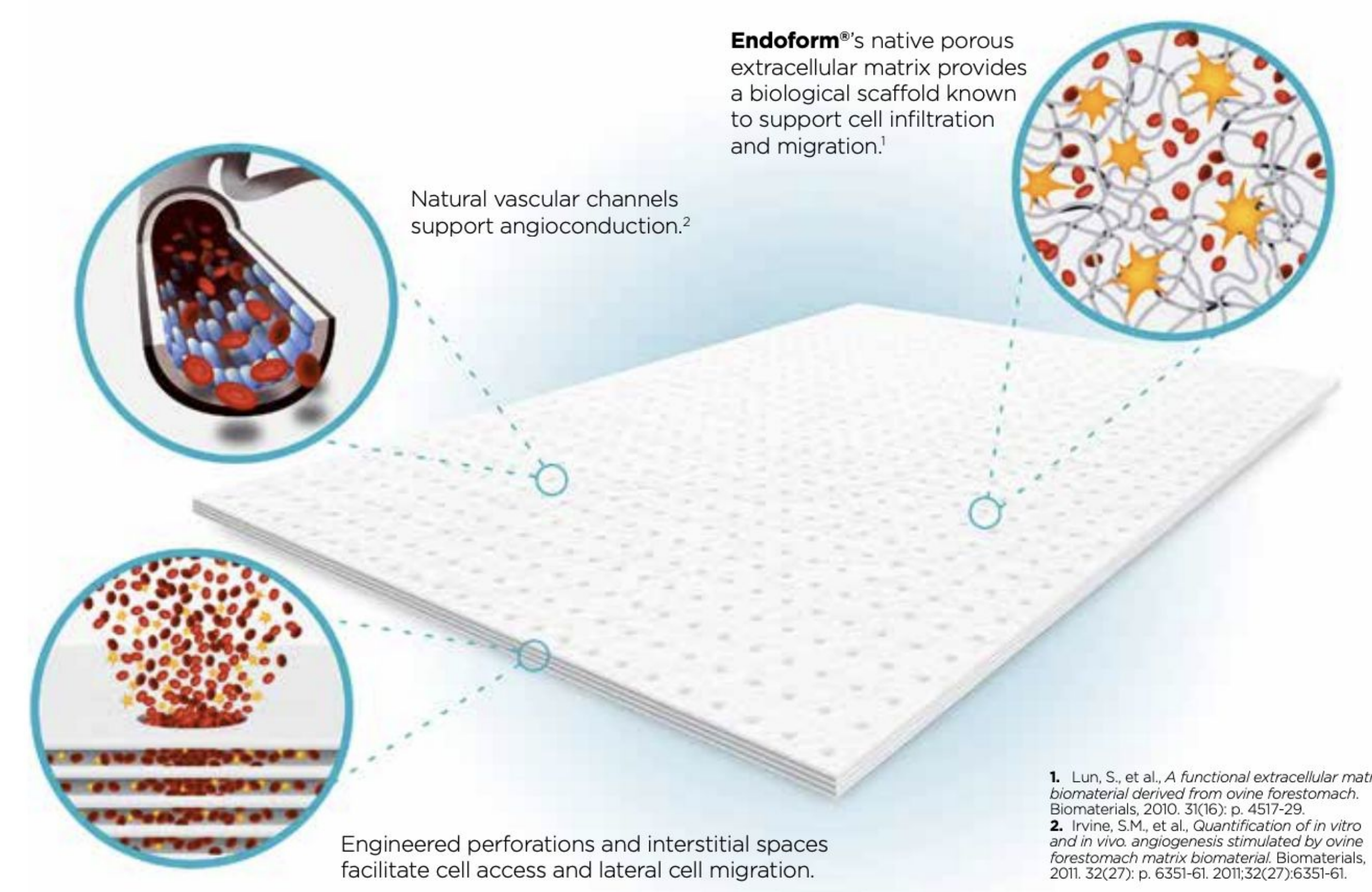
- A 69-year-old man presented to the emergency department with a chief complaint of an acute worsening of a persistent wound being cared for by infectious disease.
- The patient had a history of hidradenitis suppurativa previously treated with adalimumab.
- The bilateral buttock wounds were large, persistent, and nonhealing with severe sloughing and drainage.
- Due to the size and extent of skin involved, general surgery was immediately consulted.
- Failure of outpatient management and the severity of disease at presentation led the general surgery team to proceed with surgical debridement.
- Surgical debridement was aimed to treat the left 14x9cm open wound and right 3x3cm open wound.
- Wound vacuums and biological grafts derived from porcine urinary bladder matrix were used bilaterally to support continued drainage and tissue healing, respectively.
- The atypical bacteria and subsequent antibiotic change after cultures resulted emphasizes the importance of antimicrobial stewardship and multidisciplinary care in severe HS.

## PATHOPHYSIOLOGY



**Figure 1:** Proposed Pathogenesis of Hidradenitis Suppurativa

- Hidradenitis suppurativa arises from follicular occlusion and may evolve into subcutaneous abscesses.
- It is postulated that the lesions are due to an imbalance of cytokines and other related inflammatory factors.
- Biologic therapies are used to treat hidradenitis suppurativa and inhibit inflammatory factors such as tumor necrosis factor alpha and interleukins 1, 12, 17, and 23.



**Figure 2:** Mechanisms Underlying the Effectiveness of Biologic Grafts

## DISCUSSION

- Hidradenitis suppurativa (HS) is a chronic disease requiring long-term management and prevention of recurrence.
- Treatment varies by severity, ranging from lifestyle modification to surgical intervention.
- Nonhealing wounds impact nearly 1% of the global population, with this number expected to rise in accordance with increasing life expectancy.
- Using a graft allows the skin to be covered, thus lowering the risk of infection and allowing a moist environment, conducive to healing.
- Porcine urinary bladder matrix (UBM) grafts are an advanced wound care option, but their use in hidradenitis suppurativa (HS) is not well described in current literature.
- The goal of using porcine urinary bladder matrix was to improve graft take and allow more comfort when wounds are over irregular surfaces, such as the buttocks.

## CONCLUSION

- Ultimately, the patient was able to follow up with general surgery as an outpatient and is planning for an excision of the tissue as needed.
- In this case, emergent surgical debridement and stabilization allowed for medical optimization and safe discharge with planned outpatient follow-up.
- This case highlights the potential role of biologic grafts in managing treatment refractory complex HS wounds.
- Advanced wound care approaches, including biologic grafts, may help improve healing in severe HS.
- Further research on biologic grafts may refine treatment strategies and improve outcomes for patients with advanced HS.

## REFERENCES

1. Garg A, et al. *JAMA Dermatol*. 2017;153:760-764.
2. Goldberg SR, et al. *J Am Acad Dermatol*. 2020;82:1061-1082.
3. Frew JW. *JAAD Int*. 2020;1:62-72.
4. Napolitano M, et al. *Clin Cosmet Investig Dermatol*. 2017;10:105-115.
5. Vossen ARJV, et al. *Front Immunol*. 2018;9:2965.
6. Aroa Biosurgery. *Myriad™ Application Notes and Clinical Evidence Guide*. 2021.

## ACKNOWLEDGEMENTS

We would like to thank the faculty and staff at VCOM–Auburn as well as HCA Destin - Fort Walton Beach for their support of this project.