

## INTRODUCTION

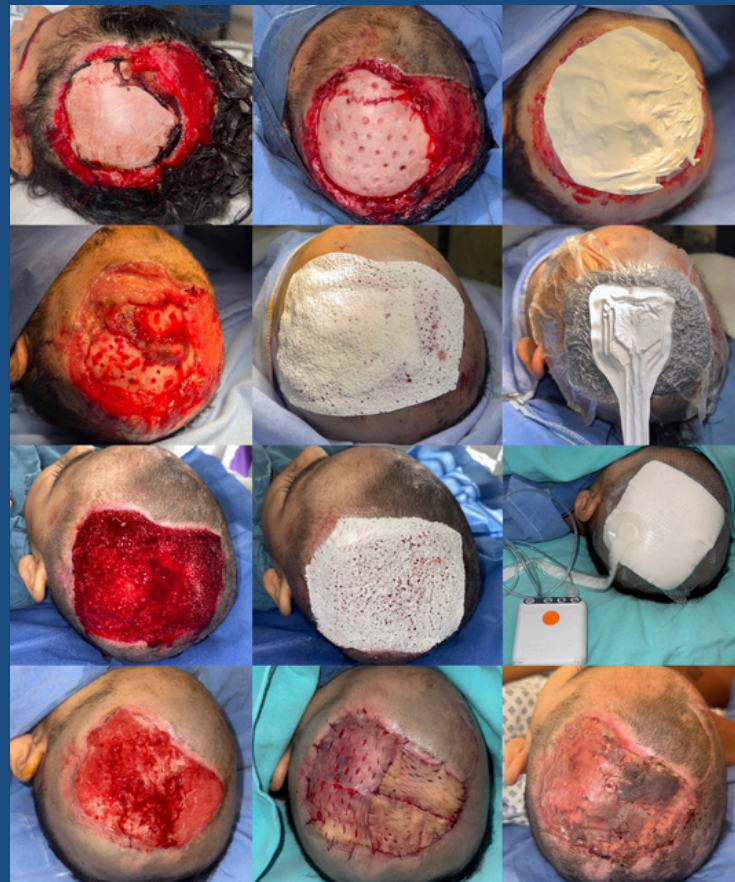
Dog bite injuries are one of the main causes of traumatic wounds in paediatric patients being recognized as an important medical and public health problem. In this case, a new level of complexity was added due to the wound location; facial and cranial injuries have a significant impact on medical management, as they are more complex to treat and more uncomfortable for the patient, often affecting their everyday life because of their functional and aesthetics implications.

## METHODS

A 2-year-old female patient, presented to the ER after sustaining a traumatic wound to the parietal region of the head, affecting almost 40% of the scalp surface caused by a dog bite. The patient was hospitalized for 32 days, during which she underwent 4 weekly surgical interventions. During the first procedure, surgical debridement was performed followed by cortical fenestration of the skull and a ppplication of a PLA membrane.

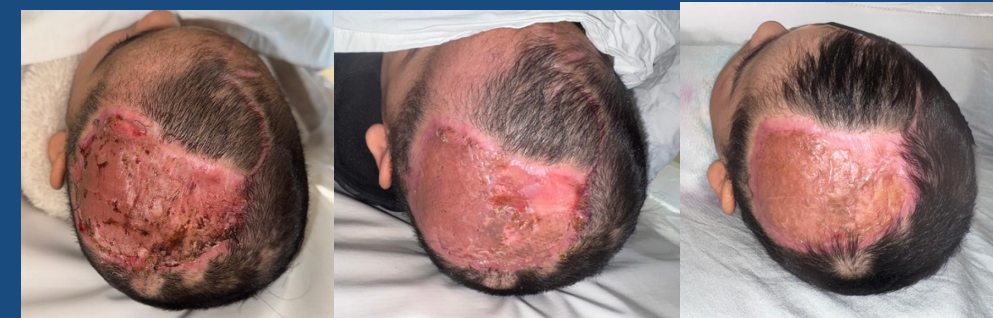The following 2 consisted of additional surgical debridement and repeated placement of PLA membranes within the wound bed, along with the use of a NPWT (Negative Pressure of Wound Therapy), first a conventional canister-based system and then a single use NPWT system.

On the last intervention partial thickness skin graft was harvested and placed, achieving full integration.



## RESULTS

The patient achieved full healing and optimal graft integration in 4 weeks, minimizing the time of hospital stay and allowing the follow up in an outpatient setting. PLA membranes were easy to use; dressing changes were performed weekly with the patient under anesthesia which improved the patients overall experience, an important consideration in pediatric care. The resulting granulation tissue had a steady progression throughout the treatment. No complications were encountered during her stay. Follow up so far, has shown a desirable integration of the skin graft and patient has reported no discomfort.



## CONCLUSIONS

PLA membranes demonstrated effectiveness temporizing scaffold, supporting granulation tissue formation and promoting favourable wound healing evolution. Its ease of use allowed for minimal dressing changes, significantly reducing the pain.

This case portraits a “fast track” approach focused on early wound closure, allowing next reconstructive phase to be strategically planned in terms of time and resource management.