

Post-Acute Care of Stalled Pressure Injuries with Placental Allografts

Brittany Ricciardi¹; Martha Kelso¹; Allyn Forsyth^{2,3}

1. Wound Care Plus LLC, Kansas City, MO; 2. MIMEDX Group, Inc., Marietta, GA; 3. Department of Biology, San Diego State University, San Diego, CA. SAWC Spring 2026

BACKGROUND

Pressure ulcer injuries (PUIs) affect over 2.5 million individuals annually in U.S. inpatient and hospital outpatient settings, making them one of the most common diagnoses in healthcare billing.¹ True prevalence is likely underestimated due to exclusion of post-acute care populations, notably skilled nursing facilities (SNF). PUIs disproportionately impact older adults with multiple comorbidities and limited mobility, contributing to significant morbidity, mortality, and economic burden—estimated at \$9.1–\$11.6 billion annually,² with individual treatment costs ranging from \$20,900 to \$152,000.¹ Advanced-stage PUIs are associated with pain, infection, sepsis, and approximately 60,000 deaths per year.

OBJECTIVE

To describe outcomes in a patient with a stalled stage-3 PUI treated with placental allografts by advanced mobile wound care providers (AMWCP)* after failure of standard care.

METHODS

The patient received an individualized treatment plan provided by AMWCP including; diagnostic monitoring (nutrition, perfusion, bioburden), education for caregivers, and standard of cares (SOC-debridement, offloading, compression, advanced dressings). When the wound failed to progress, dehydrated human amnion/chorion membrane (DHACM)** allografts were applied weekly or biweekly until closure. Wound size and characteristics were tracked longitudinally.

RESULTS

A 71-year-old male was released from an acute care hospital to a skilled nursing facility with a stage-3 sacral PUI that initiated at an unknown date. Full-thickness tissue loss, subcutaneous tissue damage, and palpable bone were observed. Three months after SNF admission, AMWCP was requested to assist with the wound that measured 38.3 cm² (Fig 1, Table 1).

*Advanced Mobile Wound Care Providers (AMWCP)= Wound Care Plus, LLC, Blue Springs, MO, US
**DHACM = EPIFIX (MIMEDX Group, Inc, Marietta, GA, US)

RESULTS

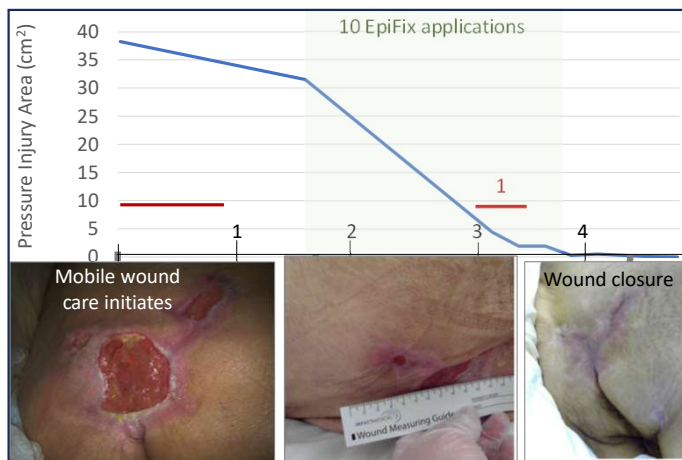


Figure 1. Closure rate of a stage-3 sacral PUI in a 71-year-old male is indicated by the blue line. AMWCP initiated at time 0. Ten DHACM applications were provided between month 1.5 to 3.5 (green shaded area). Infections occurred twice (red lines) affecting treatment timelines. Images demonstrate the progression of the wound at the indicated intervals.

Subject comorbidities included diabetes, hypertension and a total of twelve wounds of different etiologies being treated during this 5-month period. This study only followed one. The sacral ulcer required a month of rigorous SOC and infection treatment before initiating DHACM. After 1 application the area was reduced from 31.5 cm² to 10 cm². However, after 3 applications (approximately 1 month) applications were halted when signs of infection were noticed and a series of Levaquin was provided. Two weeks later DHACM was reinitiated (wound size 7.2 cm²), and full closure was achieved after a total of 10 applications. The sacral wound remained closed at a six-month check-in.

Author Affiliations

1. Wound Care Plus, Kansas City, MO
2. MIMEDX Group, Inc., Marietta, GA
3. Department of Biology, San Diego State University, San Diego, CA.

RESULTS

Table 1. Pressure ulcer injury measurement summaries*

Wound Tx	Tx (days)	W1 (cm ²)	W2 (cm ²)	WAR%	Comments
SOC	49	38.30	31.50	17.75	Care initiated with an infection.
SOC + DHACM	98	31.50	0.00	100.00	One infection event during Tx. No recurrence after six months

*Wound measurements summaries for the standard of care (SOC) and SOC with DHACM treatment periods. The periods were sequential clinician-directed treatment stages. Tx, treatment. W1, wound measurement at start of Tx period. W2, wound measurement at end of Tx period. WAR%, percent wound area reduction. DHACM, Dehydrated Human Amnion Chorion Membrane

The wound area reduction is summarized in Table 1. It is noteworthy that AMWCP treated the patient for a total of 5 months (147 days). Standard care represented 49 days (33%) of the treatment period but resulted in less than 18% of wound closure. The rate and durability of wound closure following DHACM treatment were substantial for this patient.

CONCLUSION

AMWCP combined with DHACM may offer an effective strategy for closing stalled PUIs in post-acute settings, improving outcomes and reducing complications in high-risk populations. The patient achieved complete closure following treatment escalation to DHACM despite a prolonged low-healing period under standard care. No recurrences were observed during follow-up. These findings align with prior evidence supporting DHACM efficacy in chronic wounds, including venous leg ulcers and diabetic foot ulcers.³ Larger controlled studies are warranted to confirm effectiveness and cost-benefits of DHACM for PUIs.

References

1. Lindner J. *Pressure Ulcer Statistics: Market Data Report 2025*. Accessed September 9, 2025. <https://worldmetrics.org/pressure-ulcer-statistics/>
2. *The Cost of Healthcare in Treating Pressure Ulcers*. 2025. Accessed September 9, 2025. <https://starfishofsweden.com/2025/03/06/the-cost-of-healthcare-in-treating-pressure-ulcers/>
3. Zelen CM, Serena TE, Gould L, et al. Treatment of chronic diabetic lower extremity ulcers with advanced therapies: a prospective, randomised, controlled, multi-centre comparative study examining clinical efficacy and cost. *Int Wound J*. 2016;13(2):272. doi:10.1111/IWJ.12566.

Poster development supported by MIMEDX Group, Inc.