

The Clinical Use of Acellular Intact Fish Skin Graft (pADM) as an Adjunctive Treatment for Secondary Intention Healing in Postoperative Neurosurgical Wounds

Roxana Reyna APRN, CWON-AP, Ashley Hanna MD, FAANS, Kevin S. Hopkins, MD, FACS, FAAP

Driscoll Children's Hospital | Corpus Christi, TX

Introduction

Postoperative neurosurgical wounds healing by secondary intention are difficult to manage and may require prolonged care. Acellular intact fish-skin graft (pADM) supports granulation and epithelialization. This case series evaluates its use in complex postoperative neurosurgical wounds.

Methods

Retrospective review of four patients (two neonates, one infant, one young adult) with postoperative neurosurgical wounds healing by secondary intention. Wounds were treated with acellular intact fish-skin graft and adjunctive therapies. Healing progression and outcomes were evaluated.

Results

All four wounds demonstrated progressive granulation and complete epithelialization following treatment with acellular intact fish-skin graft. Healing occurred without graft-related complications and avoided the need for additional operative repair.

Conclusions

Acellular intact fish-skin graft was a safe and effective adjunct for secondary-intention healing in complex postoperative neurosurgical wounds. In this case series, treatment supported granulation and epithelialization while avoiding additional surgical intervention.

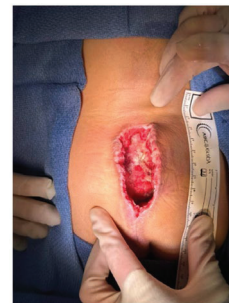CASE 1: Lumbosacral Wound

Patient History: 11-month-old preterm infant S/P Lipomyelomeningocele repair (POD 9)

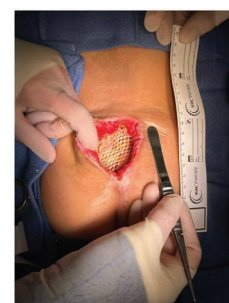Wound History: Polymicrobial infection and hematoma requiring incision and drainage. Treated with fish skin graft (FSG) and negative pressure wound therapy (NPWT). Antibiotic therapy and weekly dressing changes until healed

FSG Applications: 2

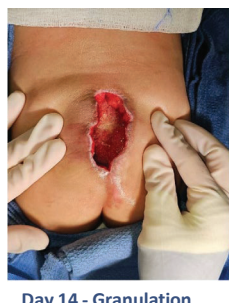Patient Outcomes: Robust granulation with complete wound closure at 84 days



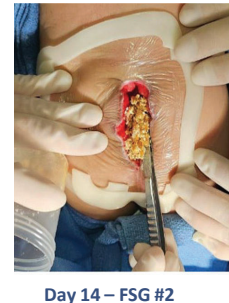
Day 0 - Initial Wound



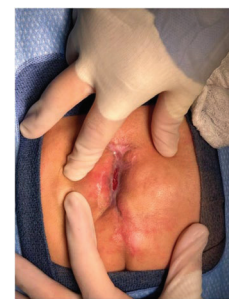Day 0 - FSG #1



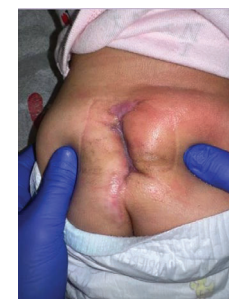Day 14 - Granulation



Day 14 - FSG #2



Day 60 - Closing



84 Days - HEALED

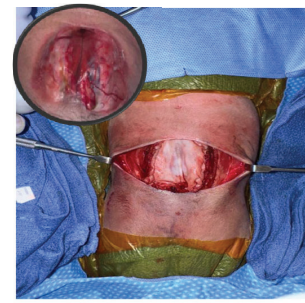
CASE 2: Complex Myelomeningocele Repair

Patient History: 37-week male neonate with open >5 cm spinal defect

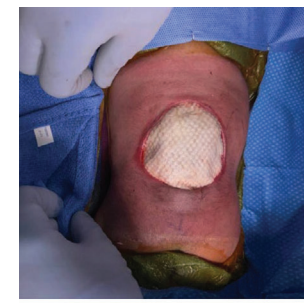Wound History: Bovine dural graft used for fascial closure; residual wound 4.5 x 7.5 cm with undermining

FSG Applications: 3

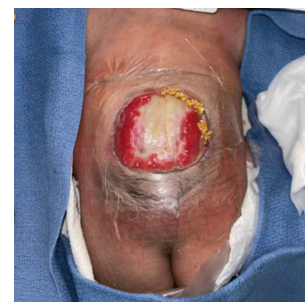Patient Outcomes: Robust granulation; complete healing at 4 months, no STSG needed



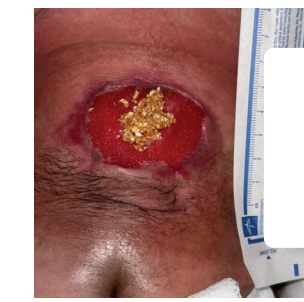Day 0 - Dural Graft



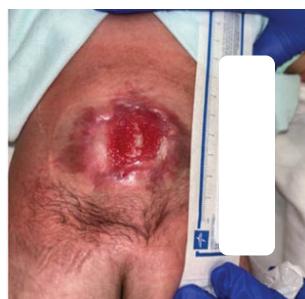Day 0 - FSG #1



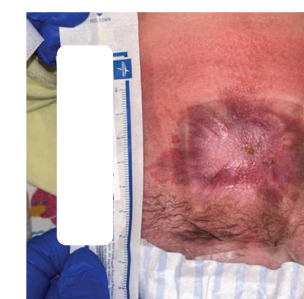
Day 21 - FSG #2



Day 50 - FSG #3



Day 69 - Granulation



120 Days - HEALED

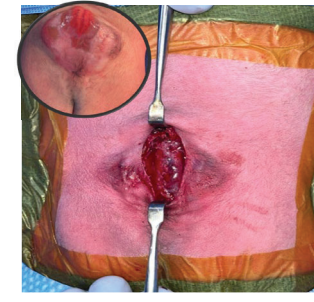
CASE 3: Myelomeningocele

Patient History: 34-week preterm infant with open spinal defect and ventriculomegaly

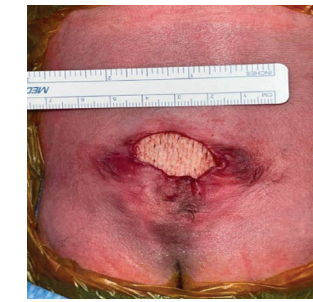Wound History: Dural and Fascial closure with bovine dural regeneration matrix; friable skin edges prevented primary closure

FSG Applications: 1 - FSG sheet placed over fascia/dural matrix with NPWT (dressing changes every 5-7 days)

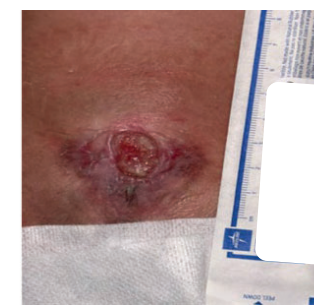Patient Outcomes: Robust granulation; wound healed at 82 days. Healing achieved in all cases within 62-120 days without need for additional surgical reconstruction



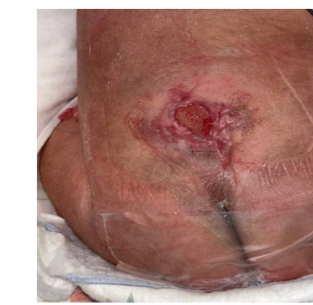Day 0 - Initial Wound



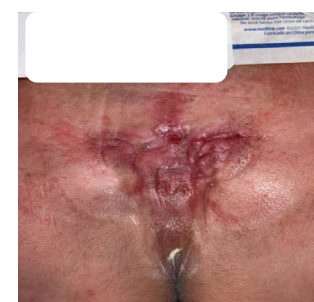Day 0 - FSG #1



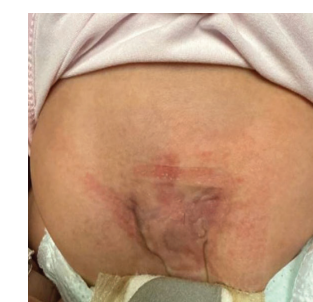Day 26 - Tissue Buds



Day 35 - Granulation



Day 56 - Closing



82 Days - HEALED

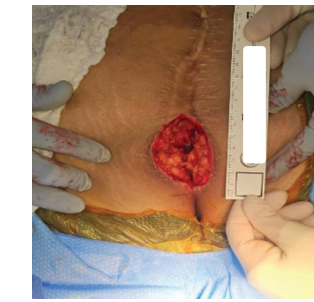CASE 4: Persistent Dermal Sinus Tract

Patient History: 18-year-old female with PMH spina bifida and prior Lipomyelomeningocele with detethering

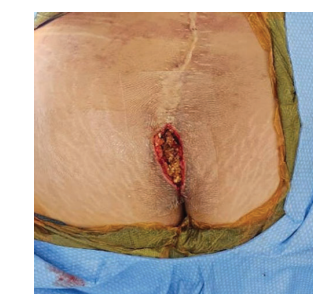Wound History: Persistent dermal sinus tract requiring incision and drainage, treated with fish skin graft (FSG) particles, medical-grade honey (MGH), and NPWT

FSG Applications: 2 -> robust granulation

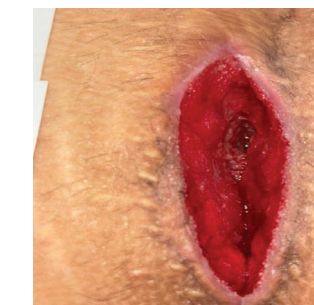Patient Outcomes: Wound healed at 62 days, 4-month follow-up: no recurrence



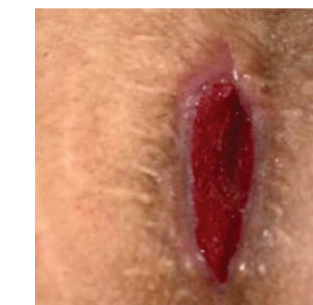Day 0 - Initial Wound



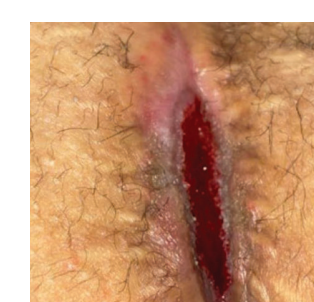Day 0 - FSG #1



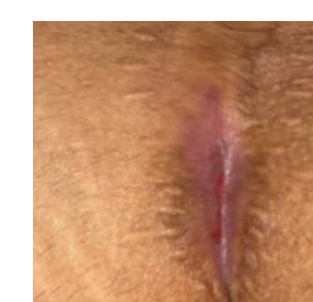Day 19 - Granulation



Day 34 - FSG #2



Day 46 - Closing



62 Days - HEALED

REFERENCES

- Ciprandi, G., Kjartansson, H., Grussu, F., Baldursson, B. T., Frattaroli, J., Urbani, U., & Zama, M. (2022). Use of acellular intact fish skin grafts in treating acute paediatric wounds during the COVID-19 pandemic: a case series. *Journal of wound care*, 31(10), 824-831. <https://doi.org/10.12968/jowc.2022.31.10.824>