

Pressure Injury Staging: Complementing Visual Assessment with Near-Infrared Spectroscopy and Thermography Imaging



Hailey Caprara, BSN, RN, CWS, DAPWCA; Nirman Tulsyan, MD, FACS, RPVI
Heritage Wound Care, Montclair, NJ 07042, USA

Introduction

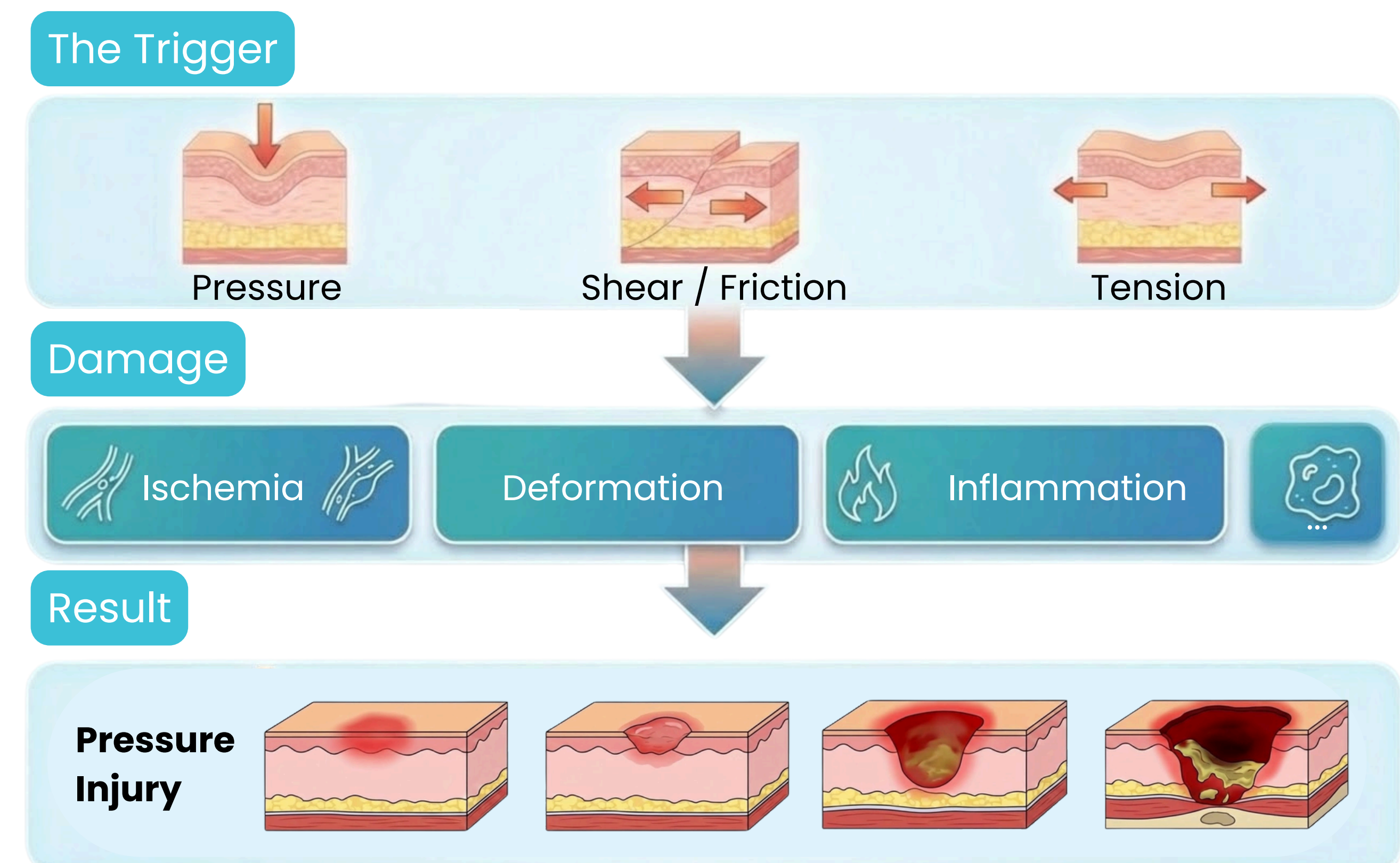
Pressure injuries (PIs) and Deep Tissue Injuries (DTIs) represent a global healthcare challenge.¹ Accurate early detection and staging of PIs is critical for effective management, yet reliance on subjective visual assessment has been associated with misstaging rates of up to 69%.² This case series compares traditional visual assessment with near-infrared spectroscopy (NIRS) and infrared thermography imaging to complement and enhance staging accuracy by detecting subsurface physiological changes. While previous studies have shown that NIRS and thermography can aid in early PI detection,³ this study investigates their potential to improve PI staging accuracy.^{4,5}

Methods

A case series was conducted involving two representative patients for each stage of pressure injury (Stages 1–4). Each case underwent a retrospective analysis using point-of-care digital photography, Near-Infrared Spectroscopy (NIRS) to assess tissue oxygenation and perfusion, and thermography to evaluate temperature variations associated with inflammation and perfusion. All modalities—thermal, oxygenation, and standard photography—were captured using the MIMOSA Pro (MIMOSA Diagnostics), an FDA-cleared Class II medical device. The study aimed to evaluate how each imaging modality characterizes physiological tissue changes across the different PI stages.

The Case for Objective Imaging

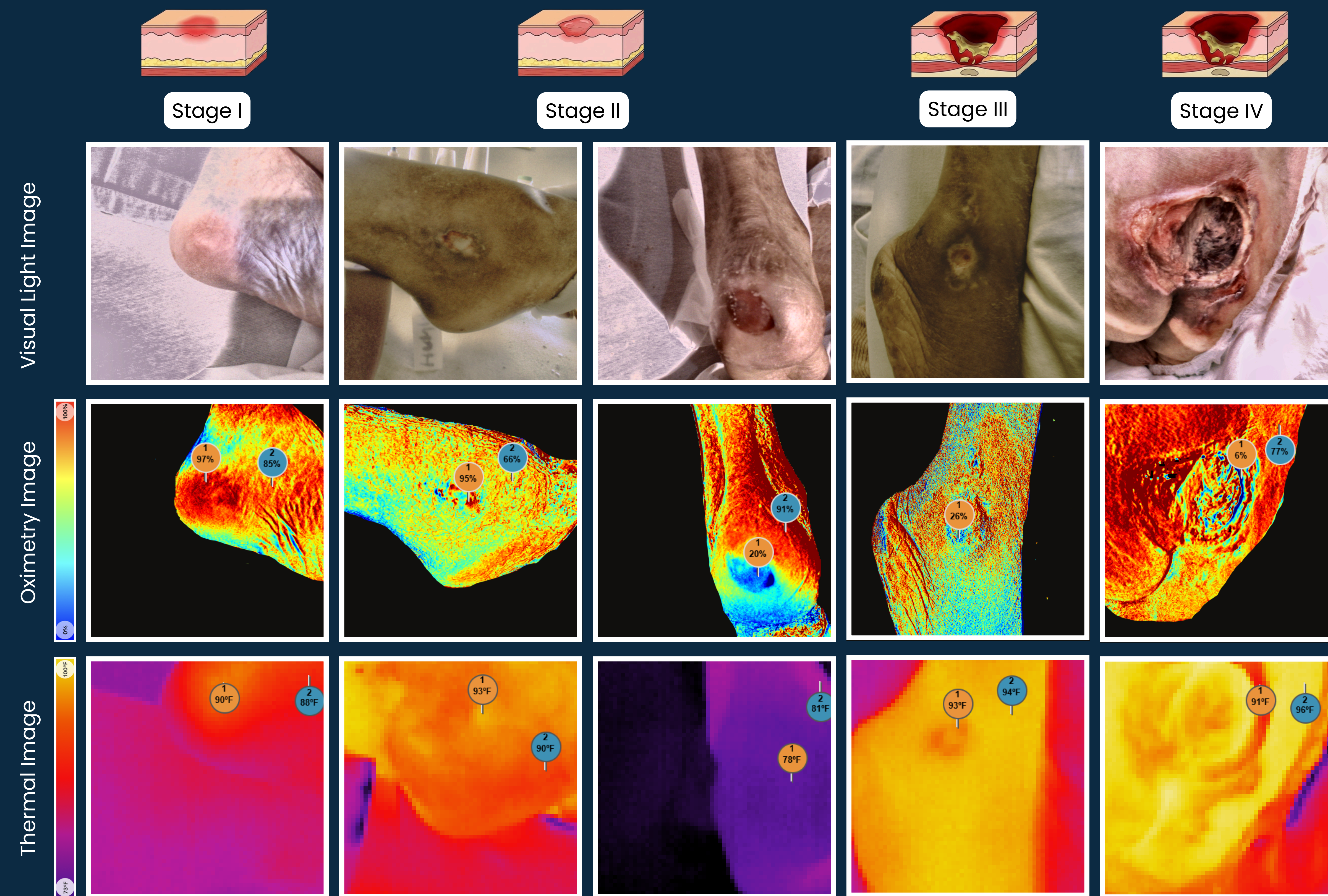
This figure summarizes the multidimensional etiology of PIs. PIs can be driven by different external forces. These forces can result in various damage mechanisms. Despite the variability in triggers and internal physiological damage, these pathways ultimately end up under the same clinical classification of PI.



Objective imaging, such as NIRS and thermography, complements visual assessment by providing clues regarding underlying damage. While visual inspection is often limited to surface changes, **NIRS identifies ischemic/reperfusion** damage through oxygenation mapping, and thermography detects **inflammation** and **perfusion** variations via **thermal mapping**.

Results

Distinct features were observed across all PI stages, yet the clinical presentation is far more complex than visual staging alone suggests. By identifying subsurface markers —such as localized decreased StO₂ (ischemia/undermining) or sharp oxygenation gradients — clinicians can differentiate between superficial inflammation and deep tissue destruction that visual assessment might miss.



- Non-blanchable erythema (redness)
- Partial-thickness vs. Full-thickness skin loss
- Presence of slough
- Palpable or exposed bone, tendon, or muscle

- Localized Decreased StO₂:
- Low StO₂
- Localized Increased StO₂:
- Oxygenation Gradients

- Localized Cold Spots
- Localized Hot Spots

Discussion & Conclusions

NIRS and thermography provide objective, non-invasive data that complement visual PI staging. These modalities may improve staging accuracy and enable earlier intervention, potentially enhancing patient outcomes. Limitations include the small sample size. Integrating NIRS and thermography into routine PI assessment could support evidence-based care and improve clinical decision-making. We plan to continue our work connecting staging and underlying etiology with the intention of providing the right treatment to the right patient at the right time

Bibliography

1. Yu, X., Zhao, J., & Zhang, N. Global Burden and Epidemiological Trends of Pressure Injuries from 1990 to 2021: Comprehensive Analysis from the Global Burden of Disease Study 2021. *Int J Low Extrem Wounds* 15347346251387455 (2025).
2. Sankovich, K., Hoffmann, R., Ren, D., & Fennimore, L. A. The Impact of Education and Feedback on the Accuracy of Pressure Injury Staging and Documentation by Bedside Nurses. *Patient Safety* 1, 10–17 (2019).
3. Tzen, Y.-T. et al. State-of-the-Art Review of Current Technology in Pressure Injury Early Detection. *Adv Skin Wound Care* 38, E128–E137 (2025).
4. Lee, L.-L. & Chen, S.-L. Assessment of Hyperspectral Imaging in Pressure Injury Healing. *Adv Skin Wound Care* 35, 429–434 (2022).
5. Pandey, B., Joshi, D. & Arora, A. S. A deep learning based experimental framework for automatic staging of pressure ulcers from thermal images. *Quant. Infrared Thermogr.* J. 22, 329–349 (2025).

