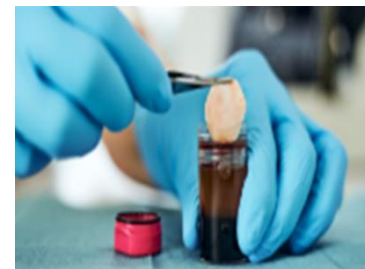

PURPOSE AND BACKGROUND

Chronic wounds are frequently characterized by impaired perfusion, tissue hypoxia, and prolonged inflammation, resulting in delayed healing and increased risk of limb loss. Autologous multilayer leukocyte-platelet-fibrin (MLPF) patches provide a biologic scaffold with sustained growth factor release and immune modulation, while hyperbaric oxygen therapy (HBOT) enhances tissue oxygenation and supports cellular repair. This therapeutic stack targets both the local wound microenvironment and systemic hypoxia. Adequate oxygen delivery is essential for angiogenesis, fibroblast proliferation, and collagen synthesis, yet chronic ischemic wounds experience persistent hypoxia and nutrient deprivation that disrupt repair mechanisms. Limited clinical data exists combining HBOT and MLPF patch therapy in complex wounds.

WHAT IS MLPF PATCH

- Produced from the patient's own blood by a proprietary, point of care, fully automated procedure
- 100% autologous
- Three-layer structure of leukocytes, platelets, and fibrin which facilitates a sustained release of living cells and growth factors into the wound bed

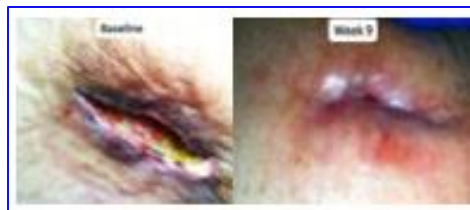


METHODS

This case series evaluated seven patients with complex wounds treated at two wound care centers. Wound etiologies include diabetic foot ulcers with and without osteomyelitis, post-amputation wounds, chronic traumatic wounds, and radiation-associated soft tissue injury. Patients received serial applications of an autologous MLPF patch prepared exclusively from the patient's own blood without exogenous additives, combined with adjunctive HBOT. Treatment sequencing, frequency, and duration varied between centers. Outcomes were assessed observationally and included percentage wound area reduction, qualitative changes in wound bed appearance, coverage of exposed structures, time to healing, and limb salvage.

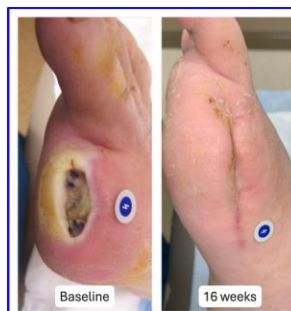CASE STUDIES

RESULTS & CONCLUSIONS



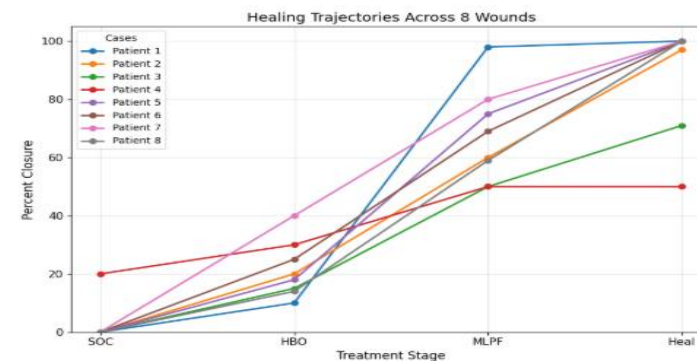
Patient

- 78 y/o Female
- Radionecrosis to left breast secondary to breast cancer. HBOT initiated at week 11 and MLPF added at week 14.
- 60 HBOT treatments, 9 applications of MLPF Patch
- **71% WAR in 9 weeks. Treatment ongoing**

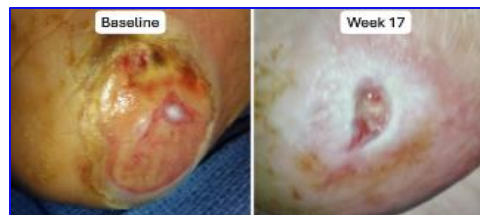

Patient

- 66y/o Male
- Rt Great toe amputation due to complications of DM2. Initiated MLPF Patch and HBOT same day. Initial measurement: 2.1cm x 0.8cm x 0.8cm
- 7 MLPF applications in 17 weeks (held therapy for 8 wks for further bone debridement)
- 61 HBOT treatments
- **Wound healed at exactly 4 months and remains closed**

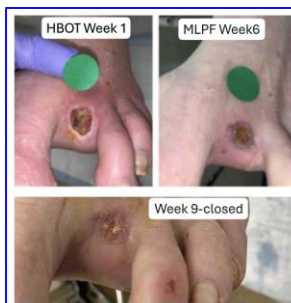

Across seven patients and eight wounds, combined autologous MLPF therapy and HBOT were associated with progressive wound improvement despite prolonged wound duration, exposed bone or soft tissue, chronic infection, and significant comorbidities. Four wounds achieved complete epithelialization; two wounds achieved greater than 90% healing at the time of analysis, and one wound remained in active treatment with approximately 50% closure. Coverage of previously exposed bone or structures was observed in all applicable cases. Limb salvage was achieved in all patients where amputation was considered a clinical risk. Two patients remained in treatment at the time of abstract submission with ongoing improvement.



Patient

- 77 y/o Female
- Wagner 2 DFU left calcaneus. HBOT initiated Week 6, and MLPF added at Week 13
- 60 HBOT treatments, 17 MLPF Patch applications
- **92.4% WAR in 17 weeks, pt currently 97% healed**



Patient

- 66 y/o Male
- Wagner 3 DFU s/p amputation due to osteomyelitis. A1C 6.5
- Initial measurement 1.3 x 1.5 x 1cm
- 3 weeks later, HBOT initiated- 1.4 x 1.2 x 0.3 cm. Pt received 11 HBOT treatments
- MLPF Patch added week 6-1.0 x 0.8 x 0.1cm. Pt received 3 weekly patches
- **Week 9 confirmed closure**