



INTRODUCTION

- Progressive care patients often undergo rapid physiological change due to **sepsis, hemodynamic instability, acute heart failure, adverse drug reactions**, and **metabolic instability**.
- These complex conditions often show **early signs of subtle skin changes** but are often *overlooked* or *misinterpreted*.
- Clinicians can benefit from **structured decision-making methods** to differentiate benign from potentially high-risk skin changes.
- Combining the specialties of a **Progressive Care Certified Nurse (PCCN®)** and **Certified Wound Ostomy Nurse (CWON®)** can improve clinical judgment and early intervention.

METHODS



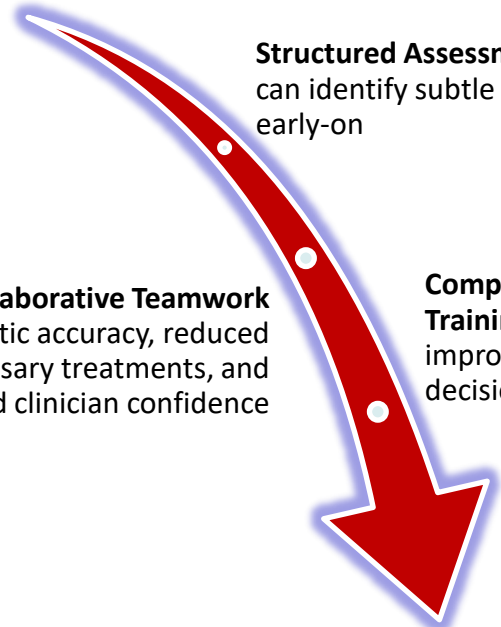
- *Published articles from 2021 to 2025.*
- *Peer-reviewed articles reviewed for relevancy*
- *Databases: OVID, PubMed, Cochrane Library*

- *Skin Assessment, Progressive Care*
- *Clinical Collaboration, Clinical Judgement*

- *Cutaneous signs of systemic decline*
- *Early identification of MASD*
- *Wound Assessment Methods*
- *Collaborative Team Models*

RESULTS

Early Signs of Physiological Instability:
Mottling, Temperature Differences,
Erythematous Rashes, Intertrigo, MASD



Structured Assessment Methods
can identify subtle skin changes
early-on

Collaborative Teamwork
diagnostic accuracy, reduced
unnecessary treatments, and
boosted clinician confidence

**Comprehensive
Training programs**
improved clinical-
decision-making

**PCCN®- CWON®
Collaborative Care Model**



DISCUSSION

- This literature synthesis highlights the importance of **combining progressive care assessment skills** with **advanced wound care expertise** to enhance clinical judgement in high-acuity settings.
- An integrated assessment model may improve **early detection of systemic decline**, limit the **progression of preventable skin breakdown**, and **support consistent collaborative clinical practices** across units.
- This interdisciplinary approach offers a foundation for developing skin and wound assessment pathways tailored to progressive care environments.
- Highlights the need for interprofessional and multi-specialty collaboration to advance clinical practice.

REFERENCES

Bakker, J., & Hernandez, G. (2020). Can Peripheral Skin Perfusion Be Used to Assess Organ Perfusion and Guide Resuscitation Interventions?. *Frontiers in medicine*, 7, 291. <https://doi.org/10.3389/fmed.2020.00291>

Fastner, A., Hauss, A., & Kottner, J. (2023). Skin assessments and interventions for maintaining skin integrity in nursing practice: An umbrella review. *International journal of nursing studies*, 143, 104495. <https://doi.org/10.1016/j.ijnurstu.2023.104495>

Franzosi, O. S., Nunes, D. S. L., Klanovicz, T. M., Loss, S. H., Batassini, É., Turra, E. E., Teixeira, C., & Vieira, S. R. R. (2020). Hemodynamic and skin perfusion is associated with successful enteral nutrition therapy in septic shock patients. *Clinical nutrition (Edinburgh, Scotland)*, 39(12), 3721–3729. <https://doi.org/10.1016/j.clnu.2020.03.033>

Gray, M., Bliss, D. Z., & McNichol, L. (2022). Moisture-Associated Skin Damage: Expanding and Updating Practice Based on the Newest ICD-10-CM Codes. *Journal of wound, ostomy, and continence nursing : official publication of The Wound, Ostomy and Continence Nurses Society*, 49(2), 143–151. <https://doi.org/10.1097/WON.0000000000000865>

Guo, Q., Liu, D., Wang, X., & Chinese Critical Ultrasound Study Group (CCUSG) (2024). Early peripheral perfusion monitoring in septic shock. *European journal of medical research*, 29(1), 477. <https://doi.org/10.1186/s40001-024-02074-1>

Pulido-Pérez, A., Bergón-Sendín, M., Suárez-Fernández, R., Muñoz-Martín, P., & Bouza, E. (2021). Skin and sepsis: contribution of dermatology to a rapid diagnosis. *Infection*, 49(4), 617–629. <https://doi.org/10.1007/s15010-021-01608-7>

For more information, please contact:
Fortunato Catanzaro: frc9055@nyp.org
Alex Aningalan: ala9173@nyp.org