

# Thermo-Reversible Wound Gel Promotes Healing by Normalizing Wound Bed pH in Chronic Wounds

Peter Moyer, DPM, Miloslav Sailer PhD, Hussam E. Itani MSc. MD, Robert B Huizinga, PhD RN

**revyve™**

ANTIMICROBIAL WOUND GEL

## Introduction:

Chronic wounds represent a major clinical challenge, affecting millions of patients worldwide and imposing substantial costs on health systems as well as profound reductions in patient quality of life. One of the key biochemical features distinguishing chronic non-healing wounds from those progressing toward closure is disruption of the normal pH profile within the wound bed.<sup>1</sup>

An alkaline wound milieu favors bacterial proliferation and biofilm formation, while simultaneously enhancing matrix metalloproteinase activity and other proteases that degrade extracellular matrix and growth factors. Elevated protease levels and sustained bioburden perpetuate a cycle of chronic inflammation, tissue destruction, and failure to progress through the normal phases of healing. **Modulating wound pH toward a more acidic (pH 4.5-6.5), physiologic range is increasingly recognized as a therapeutic target to reduce microbial load, temper protease activity, and support progression toward closure.**<sup>2,3</sup>

**pH: A key driver in unlocking wound healing**



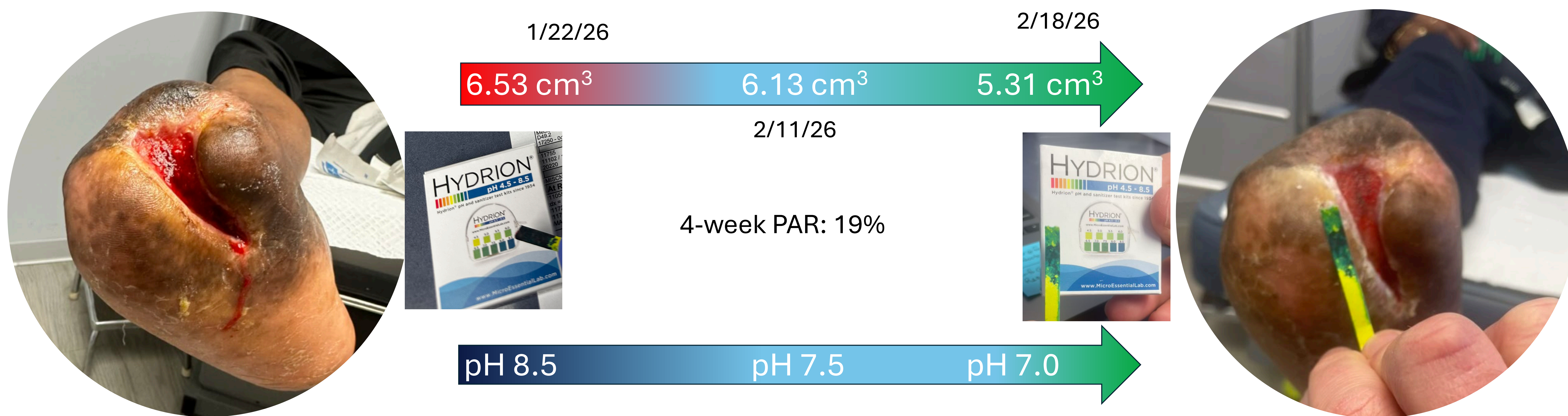
## MJ Case Description:

**Patient:** 64-year-old male with ischemic right 2<sup>nd</sup> toe wound

**Wound history:** Wound present since June 2024, which led to Trans metatarsal amputation (TMA) secondary to Peripheral Arterial Disease (PAD).

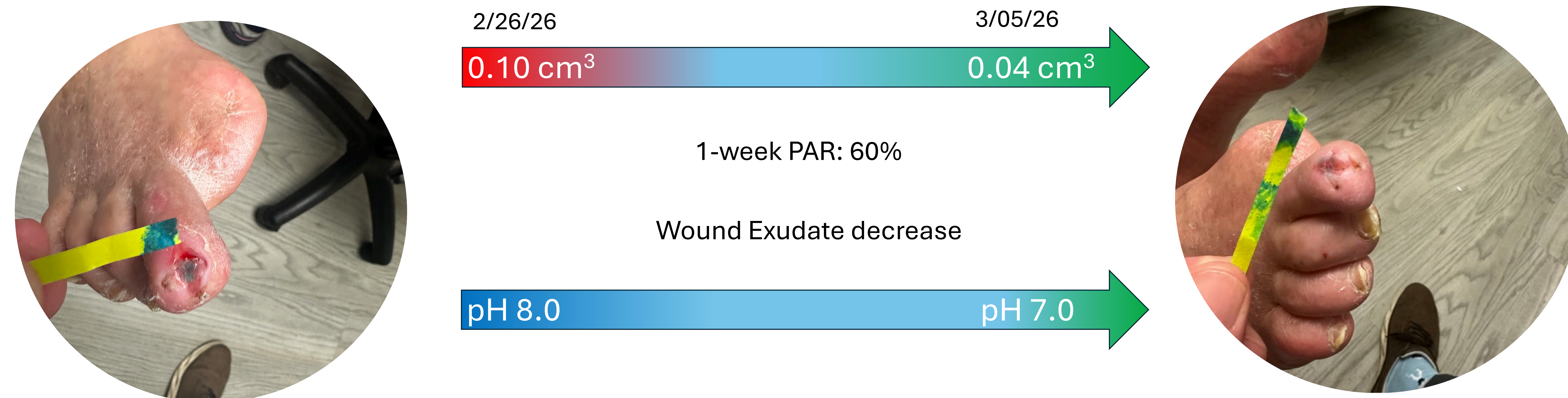
**Past Medical History:** Hypercholesterolemia, Diabetes mellitus (DM) and PAD.

**Past Surgical History:** Multiple surgical intervention on right foot  
**Previous management:** Surgical debridement, Advanced cellular matrices (ACMs) Amino acid-based products, Gentamicin, Negative pressure wound therapy (NPWT / wound VAC)  
**revyve treatment:** Started 1/22/26



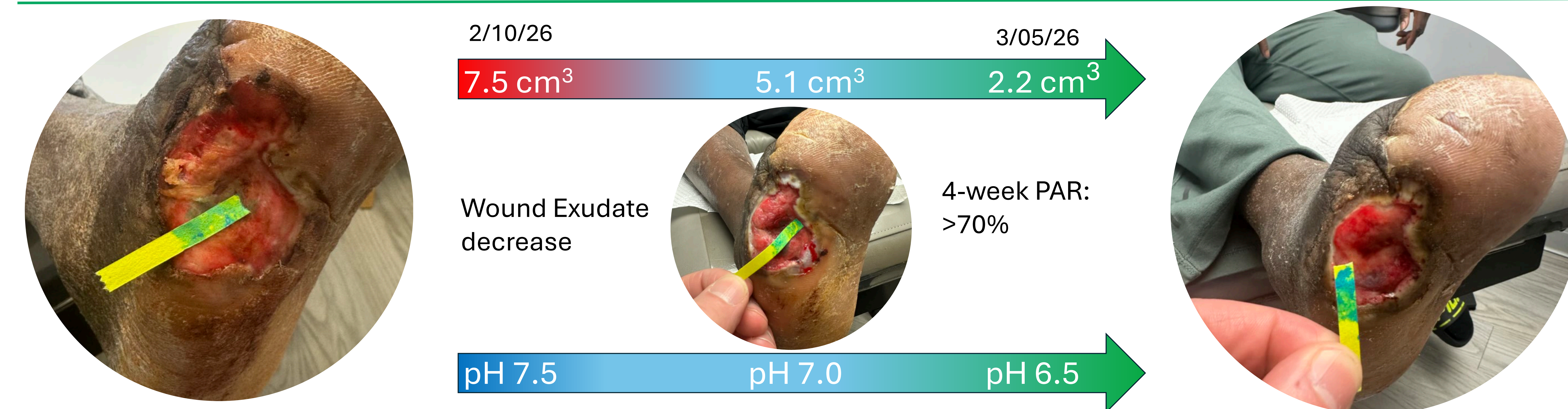
## JK Case Description:

**Patient:** 56-year-old male that presents with a chronic right 2<sup>nd</sup> toe wound with mild to moderate drainage.



## DJ Case Description:

**Patient:** Patient was admitted to hospital for OR debridement 2/5/26, the wound at this time was a Wagner 3. revyve was started on 2/10/26 to improve wound environment. The plan was to use CAMPs in 3-4 weeks for limb salvage.



## Conclusions:

The use of the revyve 3x/week in chronic wound case was associated with a meaningful normalization of wound surface pH, shifting from markedly alkaline levels at baseline toward a near-neutral environment over the course of treatment. This biochemical improvement corresponded with clear clinical benefits, including substantial reduction in wound size, improved granulation quality, and restoration of a healthier wound bed. These observations support the emerging understanding that modulation of wound chemistry, particularly correction of alkaline pH, may play a significant role in re-establishing a microenvironment conducive to healing in chronic, non-responsive wounds. Integrating pH-targeted therapies such as revyve into routine wound care may offer clinicians a practical strategy to identify stalled wounds earlier and intervene directly to address underlying biochemical barriers to repair.

<sup>1</sup>Olsson, M., Järbrink, K., Divakar, U., Bajpai, R., Upton, Z., Schmidt, S., & Car, J. (2019). The humanistic and economic burden of chronic wounds. *Journal of Wound Care*, 28(Suppl 3), S4-S13.

<sup>2</sup>Nagoba, B. S., Suryawanshi, N. M., Wadher, B. J., & Selkar, S. P. (2015). Acidic environment and wound healing: A review. *Wounds*, 27(1), 5-11.

<sup>3</sup>Serena, T. E., Hanft, J. R., Snyder, R. J., & Moore, J. C. (2016). The impact of chronic wound exudate on biofilms and protease activity. *Wounds*, 28(9), 1-7