

# ILLUSTRATIVE CLINICAL CASES FROM A RANDOMIZED STUDY EVALUATING AN AUTOLOGOUS WHOLE BLOOD-DERIVED CLOT FOR WOUND MANAGEMENT

Author: Brock Liden, DPM; Marcus Gitterle, MD; Jason Mendivil, DPM  
Cutting Edge Research, Ohio

## Background

Chronic wounds represent a significant clinical challenge due to impaired healing processes, persistent inflammation, and underlying patient comorbidities. These wounds are associated with substantial morbidity, reduced quality of life, and increased healthcare utilization. Despite the availability of advanced wound therapies, many wounds fail to progress through the normal stages of healing, necessitating additional treatment strategies that support the local wound environment.

Autologous blood-derived therapies have emerged as a promising approach in wound care due to their ability to deliver patient-derived biological components directly to the wound site. Processing of autologous whole blood can generate a cohesive clot matrix that maintains structural integrity and can be applied directly to the wound bed.

The cases presented in this poster represent selected patients enrolled in a larger randomized clinical study evaluating the clinical use of Fast Skin Patch - a point-of-care generated autologous clot for wound management. These cases illustrate the practical application of the therapy and observed wound progression in routine clinical care.

## Objective

To describe the clinical application and wound progression observed in three representative patients enrolled in a randomized clinical study evaluating a point-of-care generated autologous blood clot for wound management.

These cases highlight the practical use of the therapy during routine wound care procedures and illustrate observed changes in wound characteristics during treatment. (See Gitterle et al poster for full study).

## Methods

### Parent Study Design

The representative cases described in this report were drawn from participants enrolled in a prospective randomized clinical study evaluating the use of an autologous whole blood clot for the management of chronic wounds.

### Case Selection

Three patients were selected from the study population to illustrate clinical application of the therapy. Selection was based on availability of complete clinical documentation and serial wound assessments during the treatment period.

### Treatment Procedure

At the point of care, a small volume of autologous whole blood was collected from the patient and processed according to the study protocol to generate a self-supporting clot matrix. The clot was transferred directly onto the prepared wound bed during routine wound care procedures and conformed to the wound dimensions to achieve full coverage of the wound surface. Following placement, the clot

was covered with a standard secondary dressing as part of the ongoing wound management protocol.

## Clinical Assessment

Wound progression was evaluated using routine clinical assessments performed during scheduled follow-up visits. Measurements included wound size, visual assessment of the wound bed, and photographic documentation.

## Results

Complete wound closure was achieved in 3/3 patients (100%) within 12 weeks. Time to healing occurred at treatment visit (TV) 6 (n=1), TV8 (n=1), and TV10 (n=1)

Early development of granulation tissue was observed during the initial treatment visits, followed by progressive wound contraction and epithelialization leading to complete closure.

No device-related adverse events were observed.

## Conclusion

These representative cases demonstrate the practical clinical application of a point-of-care generated autologous blood clot during routine wound management.





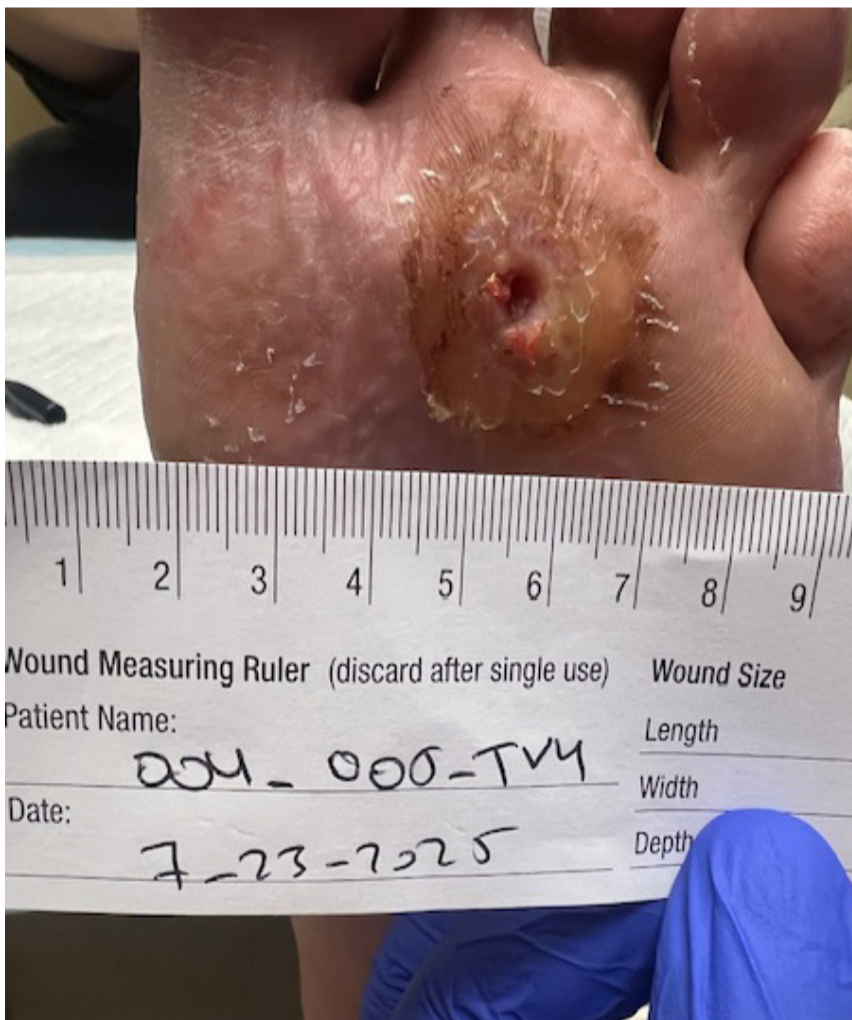


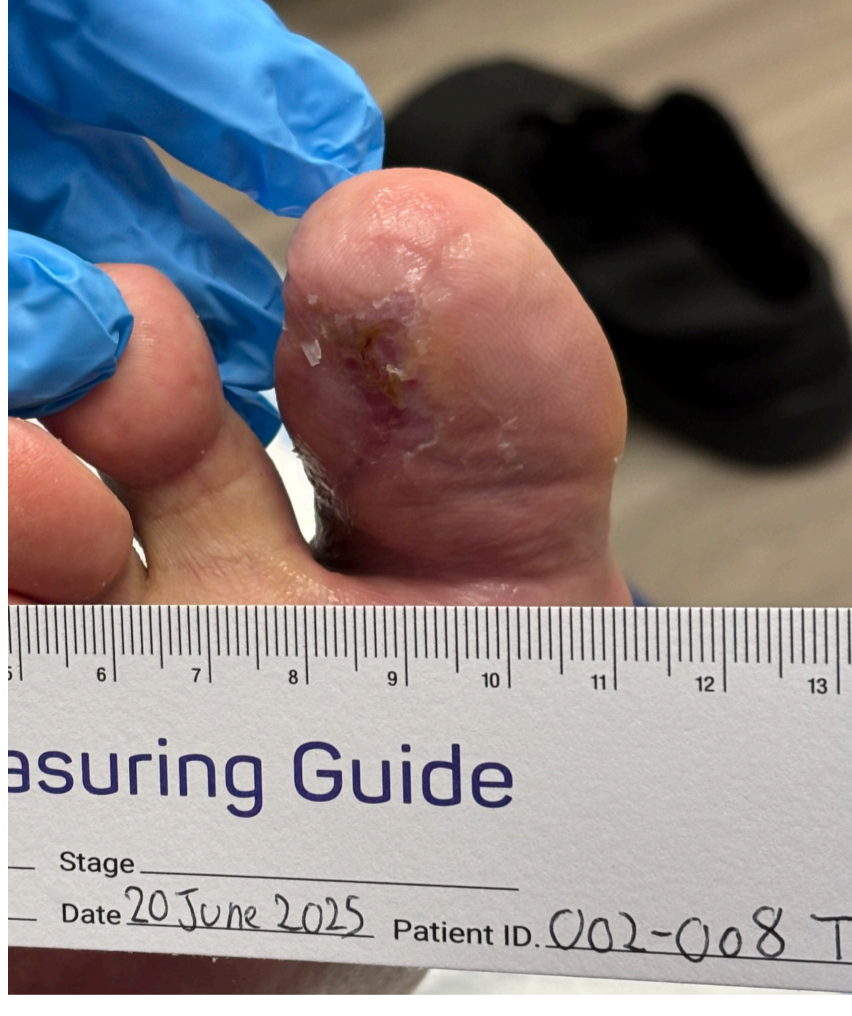
The clot maintained structural integrity during placement and was readily adapted to wound geometry. Observed wound progression in these patients suggests potential utility of this approach and warrants further evaluation in additional randomized clinical studies.

FastSkin Patch may provide clinicians with a biologically derived wound management system that can be adapted to wound dimensions and incorporated into standard wound care workflows.

### Patient Overview & Clinical Progression

Patient	Age	Sex	Ulcer duration	Ulcer location	Baseline size (cm2)	Mid-treatment	Healed at TV
004_003	53	F	3 months	Left Leg, Plantar, Midfoot	TV1 - 2.38 cm <sup>2</sup>	TV5 - 0.2 cm <sup>2</sup>	TV10 - closed
004_005	61	M	10 months	Left Leg, Plantar forefoot	TV1 - 1.1 cm <sup>2</sup>	TV4 - 0.12 cm <sup>2</sup>	TV8 - closed
002_008	56	M	3 months	Right Leg, Plantar, Forefoot, 1 <sup>st</sup> Toe	TV1 - 3.0 cm <sup>2</sup>	TV3 - 0.64 cm <sup>2</sup>	TV6 - closed

### Wound Progression Panel

Patient	Baseline	Mid-treatment	Healed
004_003	 TV1 - 2.38 cm <sup>2</sup>	 TV5 - 0.2 cm <sup>2</sup>	 TV10 - closed
004_005	 TV1 - 1.1 cm <sup>2</sup>	 TV4 - 0.12 cm <sup>2</sup>	 TV8 - closed
002_008	 TV1 - 3.0 cm <sup>2</sup>	 TV3 - 0.64 cm <sup>2</sup>	 TV6 - closed

