

# 3D Bioprinting Adipose Grafting for Soft Tissue Repair, My Experience

Michael N. Desvigne MD, FACS, CWS, FACCWS, MAPWCA, Krista Bauer, F NP, WCC, OMS, Jody Wolfe, BSN, MBA, RN, CWOCN, Cynthia Koehler, MD, Ava Koehler De Celaya, MS1

## INTRODUCTION

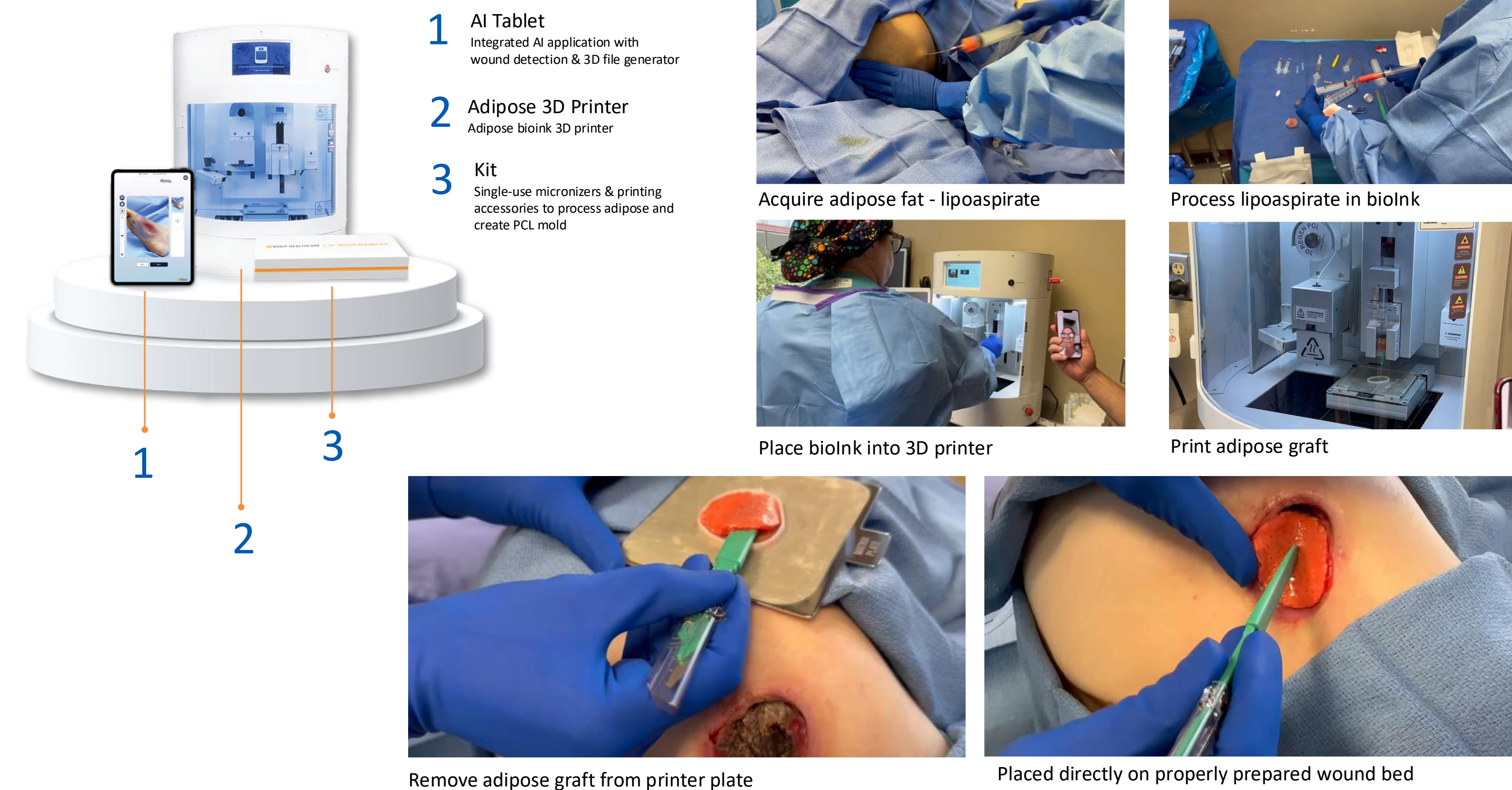
Autologous fat grafting is commonly used for aesthetic and reconstructive surgery of the breast and other areas in attempts to reverse long term effects of radiation and scar. The value of autologous minimally manipulated homologous adipose tissue (AMHAT) has been described as a potential source of stimulation of proliferative and interactive cells. However, techniques have been limited to allow for practical use.<sup>1</sup>

(AMHAT) fabricated using three-dimensional (3D) bioprinting has shown potential in the treatment of diabetic foot ulcers and other chronic wounds.<sup>2-7</sup> Is adipose the holy grail for soft tissue repair? 3D printing utilizing bioinks to create a customized adipose graft for a patient is the ultimate personalization of point of care and indeed may be the future.

## METHODS

We present our early experience with 3D adipose printing for patients with pressure ulceration. 2 Patients were treated with 3D adipose printed grafts\*. Each patient underwent 2 procedures, performed in the outpatient clinic under local anesthesia with small volume (15-20cc) liposuction obtained from the trunk. 3D bioprinting was utilized to customize the graft size and then processed and printed. The graft was placed on the wound site. Two methods were utilized, low-temp method and fibrin method yielding different physical attributes, textures, and pliability of the adipose graft. The wounds were photographed and measured weekly.

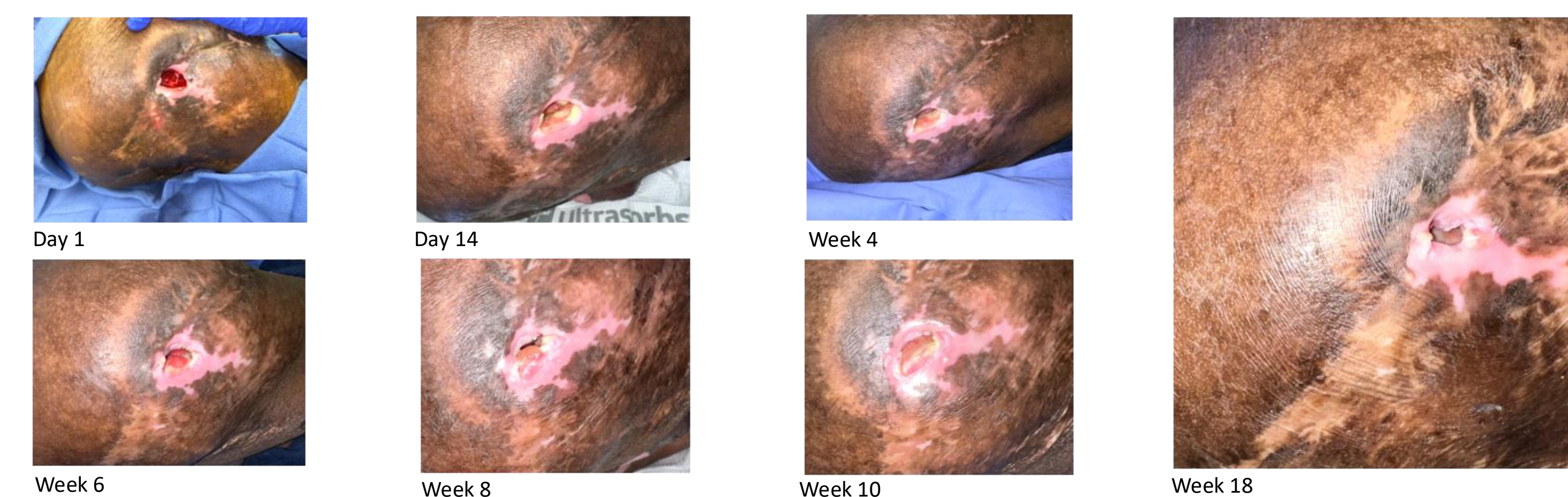
## METHODS



## RESULTS

All wounds showed wound progression including reduction of size and depth with evidence of epithelialization. One patient elected to proceed with surgical flap closure. Upon excision of the wound prior to flap closure, the excised specimen was analyzed histologically and showed clear evidence of neo-angiogenesis, keratinocyte and epithelial migration.

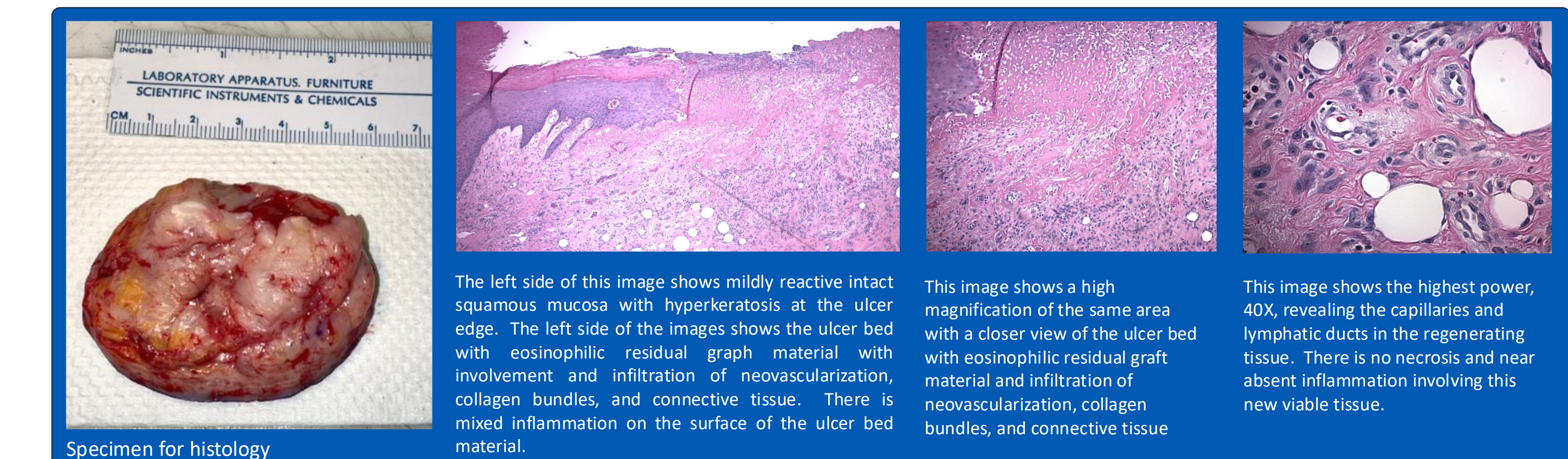
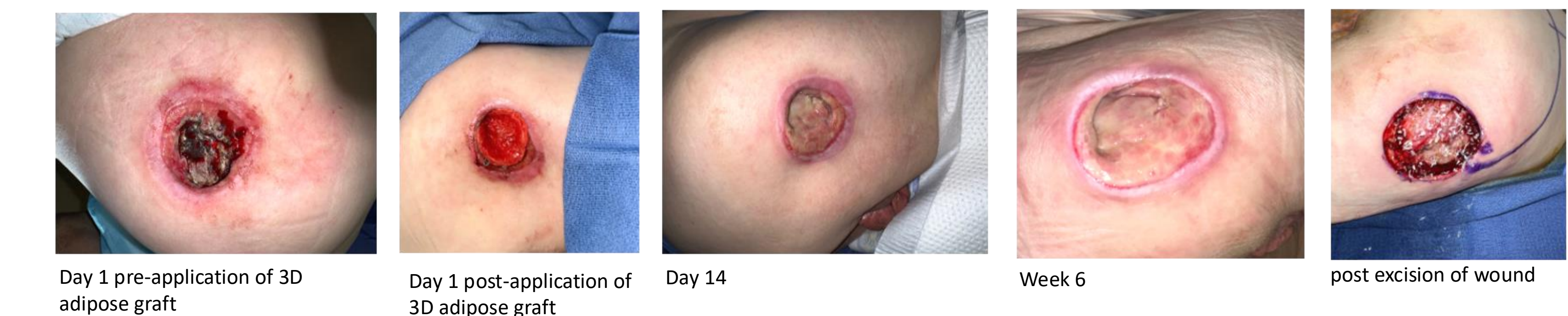## Patient 1



Showned wound progression with a reduction of wound size by 23% and depth by 38% after 6 weeks. 64 yo male with paraplegia for 30 years presents with recurrent pressure ulcer right hip, deemed poor candidate for additional surgery. Surgical History: Multiple procedures for pressure injury. Medical history: CAD, HTN, Smoker

## Patient 2

Showned wound progression with a reduction of wound size by 40% and depth 33% at 6 weeks. Furthermore, Patient 2 requested additional procedures for a new ulcer that appeared on the contralateral side.



## CONCLUSION

New technology utilizing adipose as an adipose 3D printed matrix creates a personalized point of care delivery system for patients with complex wounds. Use of tissue in excess to create tissue on demand is the “Holy Grail” of wound management and soft tissue reconstruction.

\* APLICOR™ 3D Bioprinter, Tides Medical

## References

1. Matsumura, R., Matsumura, H., Kawai, Y., Kim, J., Lee, M.-C., Yu, Y., Fujii, M., Shimada, K., Komiya, T. Three-Dimensional Bioprinted Autologous Minimally Manipulated Homologous Adipose Tissue for Skin Defects After Wide Excision of Skin Cancer Provides Early Wound Closure and Good Esthetic Patient Satisfaction. *J. Clin. Med.* 2025, 14, 1795. <https://doi.org/10.3390/jcm14061795>
2. Namgoong et al. "A Pilot Study Comparing a Micronized Adipose Tissue Niche versus Standard Wound Care for Treatment of Neuropathic Diabetic Foot Ulcers" *J. Clin. Med.* 2022, 11, 5887 <https://doi.org/10.3390/jcm11195887>
3. Yoon et al. "Grafting Low-Temperature Micronized Adipose Tissue Niche to Treat Diabetic Foot Ulcer: A Pilot Study". *J Wound Manag Res* 2023 June;19(2):102-108. <https://doi.org/10.22467/jwmr.2023.02509>
4. Bajuri et al. "New Paradigm in Diabetic Foot Ulcer Grafting Techniques Using 3D-Bioprinted Autologous Minimally Manipulated Homologous Adipose Tissue (3D-AMHAT) with Fibrin Gel Acting as a Biodegradable Scaffold" *Gels* 2023, 9, 66. <https://doi.org/10.3390/gels9010066>
5. Armstrong et al. "Autologous Minimally Manipulated Homologous Adipose Tissue (AMHAT) for Treatment of Nonhealing Diabetic Foot Ulcers" *Plast Reconstr Surg Glob Open* 2022;10:e4588;doi:10.1097/GOX.0000000000004588
6. Kesavan et al. "Management of Diabetic Foot Ulcer with MA-ECM (Minimally Manipulated Autologous Extracellular Matrix) Using 3D Bioprinting Technology – An Innovative Approach" *The International Journal of Lower Extremity Wounds*; 1-8. 2021. doi:10.1177/15347346211045625
7. Yasti et al. "Graft of 3D Bioprinted Autologous Minimally Manipulated Homologous Adipose Tissue for the Treatment of Diabetic Foot Ulcers" *Wounds.* 2023;35(1):E22-E28. doi:10.25270/wnds/21136

## Author Affiliations

1. Plastic and Reconstructive Surgery, Wound Care and Hyperbaric Medicine, Abrazo Arrowhead Hospital and Wound Clinic, Glendale, AZ

Corresponding author email: mdesvigne@desvignemd.com