

Imaging study of enhanced CT combined with clinical indicators in the differential diagnosis of severe and moderately severe acute necrotizing pancreatitis

Yue Feng¹, Bo Xiao^{1*}

¹Department of Radiology, Bishan Hospital of Chongqing Medical University, Bishan Hospital of Chongqing, Chongqing, China

BACKGROUND

Acute necrotizing pancreatitis (ANP), a more severe form of acute pancreatitis, requires early diagnosis and accurate severity stratification for optimal patient prognosis and treatment. Currently, most scholars do not clearly differentiate between acute necrotizing pancreatitis and severe acute pancreatitis (SAP), although they are distinct clinical entities.

METHODS

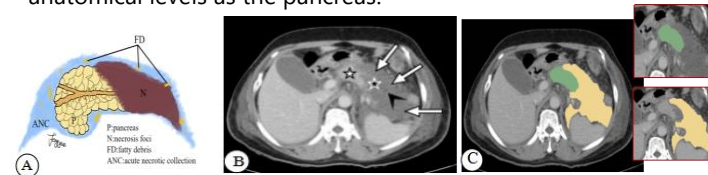We conducted a retrospective study of 184 ANP patients (72 severe, 112 moderately severe), randomly divided into training and test cohorts in a 7:3 ratio. On portal venous phase CECT images, regions of interest (ROIs) encompassing the entire pancreatic parenchyma and peripancreatic necrotic collections were manually delineated on a slice-by-slice basis. Radiomic features were then extracted from the ROIs using the PyRadiomics package. Feature selection was performed using intraclass and interclass correlation coefficients (ICCs), independent samples t-tests, and the Light Gradient Boosting Machine (LightGBM) algorithm. The classification models were constructed using support vector machine (SVM), random forest (RF), k-nearest neighbor (KNN), gradient boosting decision tree (GBDT), and extreme gradient boosting (XGBoost) algorithms combined with 10-fold cross-validation, developing three distinct models: the pancreatic model (based on pancreatic parenchyma), the peripancreatic model (based on peripancreatic necrotic collections), and the combined model (integrating both regions). The performance of each model was evaluated by analyzing receiver operating characteristic (ROC) curves, the area under the curve (AUC), accuracy, sensitivity, specificity, F1-score, and Brier score.

REFERENCES

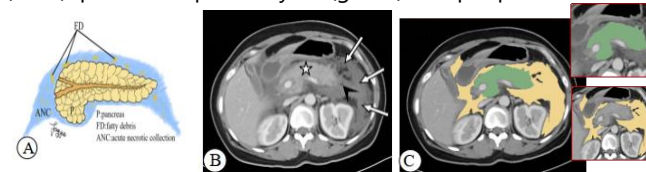
Yu NJ, et al. Radiomics models of contrast-enhanced computed tomography for predicting the activity and prognosis of acute pancreatitis. *Insights Imaging* 2024; 15: 158

RESULTS

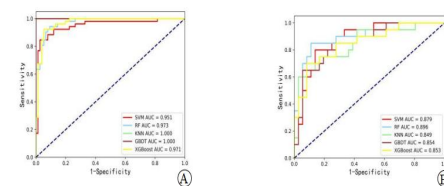
1. Mixed pancreatic necrosis. A: Schematic of mixed pancreatic necrosis: necrotic foci (N) in the pancreatic body and tail with peripancreatic fatty debris (FD); B: Portal venous CECT in a 55-year-old female with mixed necrosis shows parenchymal necrosis (black star), peripancreatic necrotic collections (white arrows) containing fatty debris (black arrowhead), and residual normal pancreas (white star); C: Corresponding ROIs: green area manually delineates the entire pancreatic parenchyma (necrotic tissue included; ducts and vessels excluded); yellow area represents peripancreatic necrotic collections at the same anatomical levels as the pancreas.



2. Rperipancreatic necrosis only. A: Schematic of peripancreatic necrosis only: fatty debris (FD) in peripancreatic adipose tissue without necrosis of the pancreatic parenchyma; B: Portal venous phase CECT in a 43-year-old male with peripancreatic necrosis only reveals peripancreatic necrotic collections (white arrows) containing scattered fatty debris (black arrowheads). Normal pancreatic parenchyma is indicated by a white star; C: Corresponding manually delineated regions of interest (ROIs): pancreatic parenchyma (green) and peripancreatic necrotic collections (yellow).



3. ROC curves of radiomics-based discrimination models developed using five machine learning algorithms (SVM, RF, KNN, GBDT, and XGBoost) for combined pancreatic parenchyma with peripancreatic necrotic collections. A: training cohort; B: test cohort.



The combined RF model demonstrated superior performance compared to other models (SVM, KNN, GBDT, and XGBoost) for differentiating between severe and moderately severe ANP. It achieved the best results in the test cohort, with an AUC of 0.896 (95% CI: 0.778-0.977), accuracy of 0.839, sensitivity of 0.650, specificity of 0.944, F1-score of 0.743, and Brier score of 0.134.

CONCLUSION

Radiomic analysis of both the pancreatic parenchyma and peripancreatic necrotic collections on CECT, combined with machine learning, effectively differentiates between severe and moderately severe ANP. The combined RF model showed superior performance. This approach shows potential for improving early diagnostic accuracy, aiding clinical decision-making, and optimizing treatment strategies. The refined classification system facilitates better resource allocation, patient triage, and stratification.

Table 1 Comparison of clinical outcomes and treatment modalities between ANMSP and ANSP

Characteristics	MSAP (n=112)	SAP (n=72)	Z/ χ^2 /Fisher's exact test	P
Length of stay	11.00(8.00, 16.00)	16.00 (10.00, 20.75)	-3.562	< 0.001 ^a
ICU admission	no 112 (100.00)	60 (83.33)	17.329	< 0.001 ^a
	yes 0 (0.00)	12 (16.67)		
Mortality	no 112 (100.00)	70 (97.22)	-	0.152
	yes 0 (0.00)	2 (2.78)		
Surgery/Intervention	no 100 (89.29)	54 (75.00)	6.554	0.010 ^a
	yes 12 (10.71)	18 (25.00)		

^a indicates $P < 0.05$, representing a statistically significant difference.