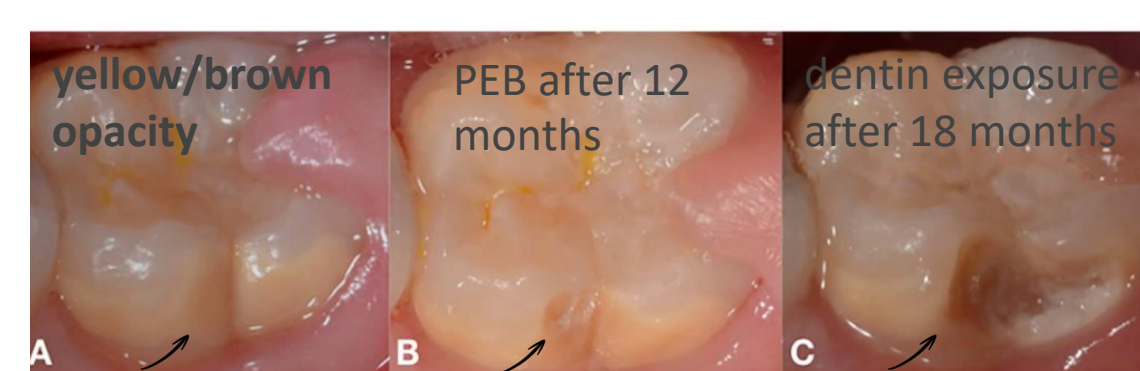

Ana Aparecida Perucio Camargo Morschel DDS¹, Shlomo Elbahary DMD, PHD³, Kelly Fernanda Molena DDS, PHD², Scott Tomar DMD, DrPH⁴, Grace Viana BSc, MSc⁵, Leda Mugayar DDS, MS⁴

1 Department of Pediatric Dentistry, UIC College of Dentistry **2** Department of Pediatric Dentistry, USP School of Dentistry Ribeirão Preto, Brazil
3 Department of Endodontics, UIC College of Dentistry **4** Department of Population Oral Health, UIC College of Dentistry **5** Department of Orthodontics, UIC College of Dentistry

BACKGROUND

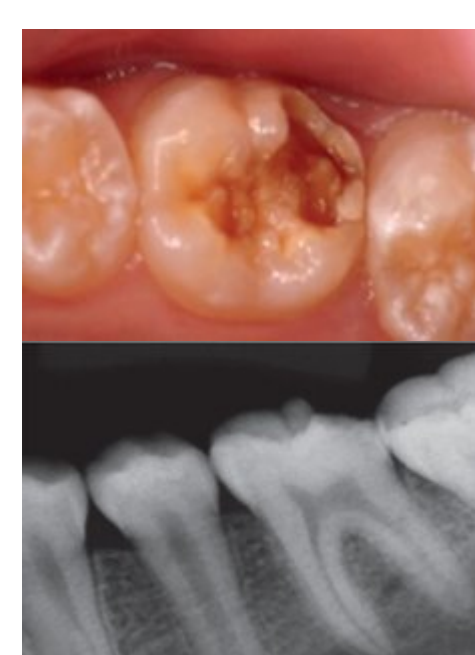

Cabral, R et al., 2020.

Molar-Incisor Hypomineralization (MIH) is a developmental enamel defect affecting one or more permanent first molars, often with associated involvement of incisors. Characterized by structural weakness, hypersensitivity, and increased risk of post-eruptive enamel breakdown (PEB).

OBJECTIVES

The aim of this study was to evaluate the diagnostic potential of panoramic radiographs for identifying MIH in the permanent dentition of children and to compare the diagnostic performance of pediatric dental specialists with that of other dental professionals.



AlKhalaf R et al., 2022.

METHODS

Retrospective observational Analysis;
Clinician-Based Diagnostic Evaluation

Analysis Tool:
SPSS 31.0

Demographics:

Age,
Gender,
Race,
Ethnicity



Variables:

Opacity
Post-eruptive breakdown (PEB)
Dentin exposure
Atypical caries
Nolla stage
Eruption status

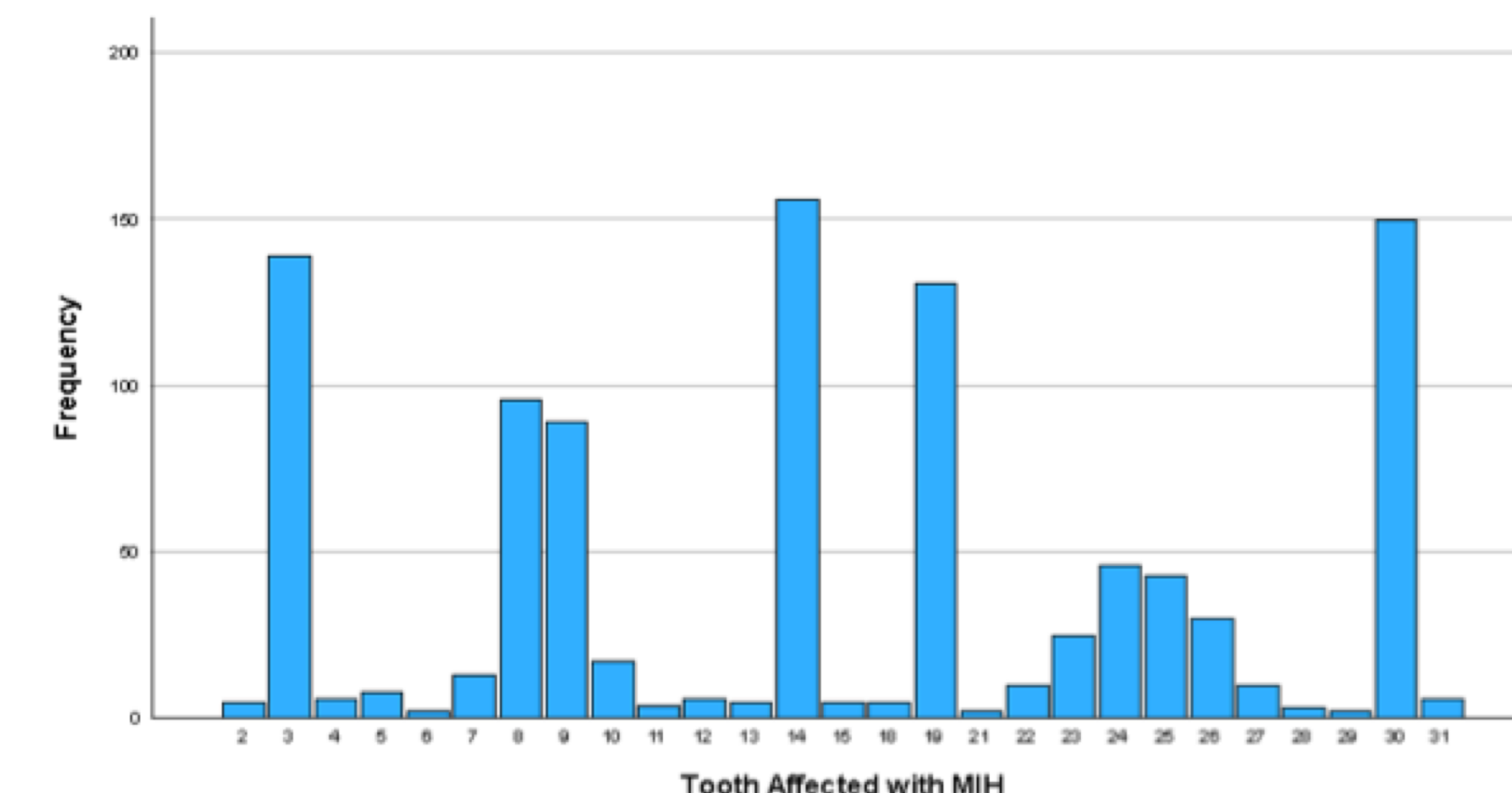
Participants:

11 Pediatric Dental Specialists
5 General Dentists and 4 Dentists from other specialties
(Total: 20 clinicians)

IRB Protocol #2024-0837

RESULTS

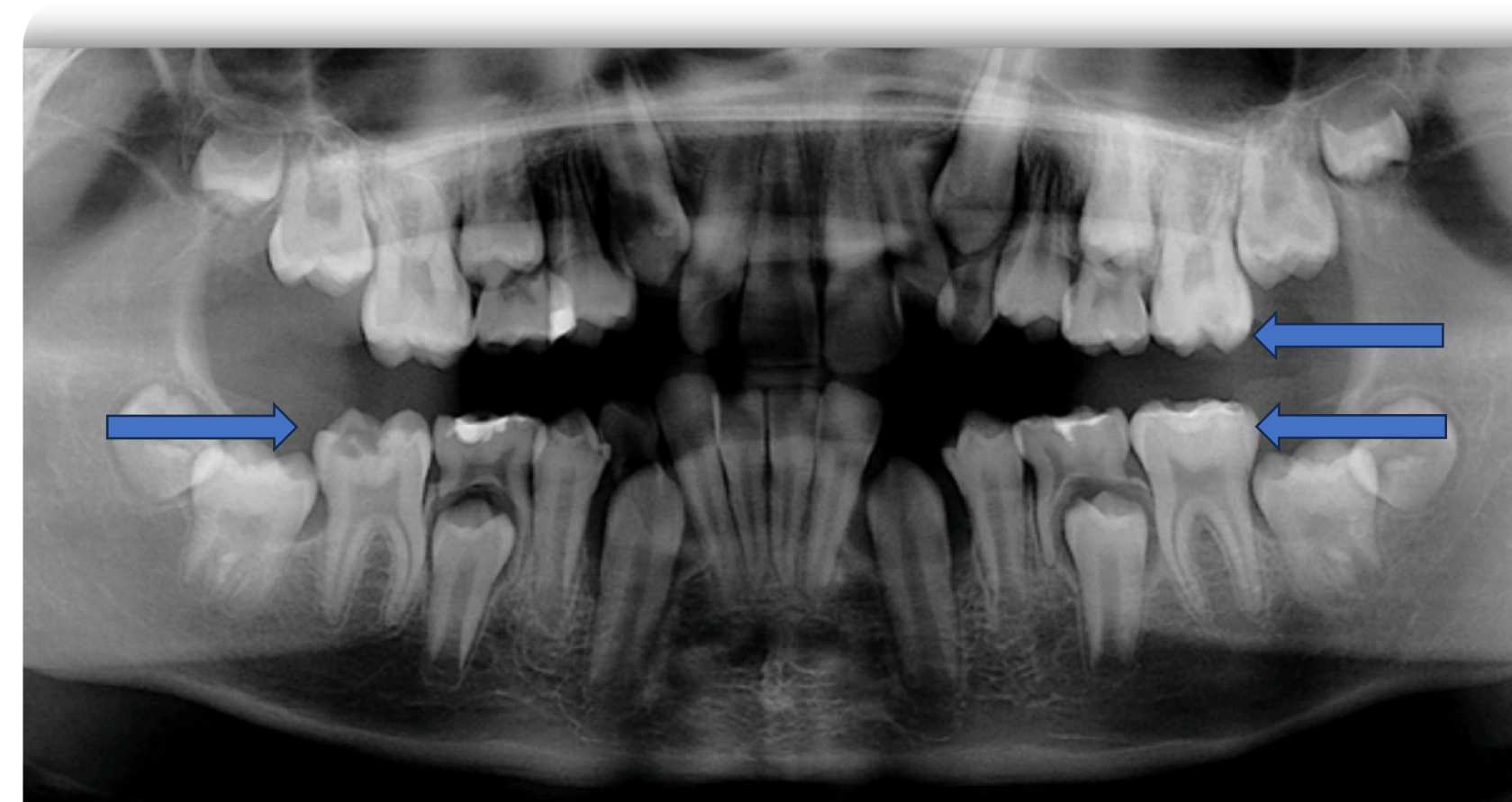- N = 292 valid cases
- Mean age: **8.34** years
- Sex: **47.9%** female, **52.1%** male
- Ethnicity: **60.7%** White, **13.4%** Black, **4.1%** Asian, **21.7%** declined.



Significant findings: Surfaces vs. opacity/PEB (p < 0.001)

| Defect type | One surface (%) | Two surfaces (%) | ≥3 surfaces (%) |
|-----------------------------|-----------------|------------------|-----------------|
| Opacity | 66.5 | 10.1 | 23.3 |
| PEB without dentin exposure | 52.1 | 9.2 | 38.7 |
| PEB with dentin exposure | 24.0 | 13.0 | 63.0 |
| MIH atypical caries | 53.3 | 20.0 | 26.7 |

Table 1. MIH defect type and number of affected surfaces



COD Pediatric Dentistry Dep Patient Axium Data

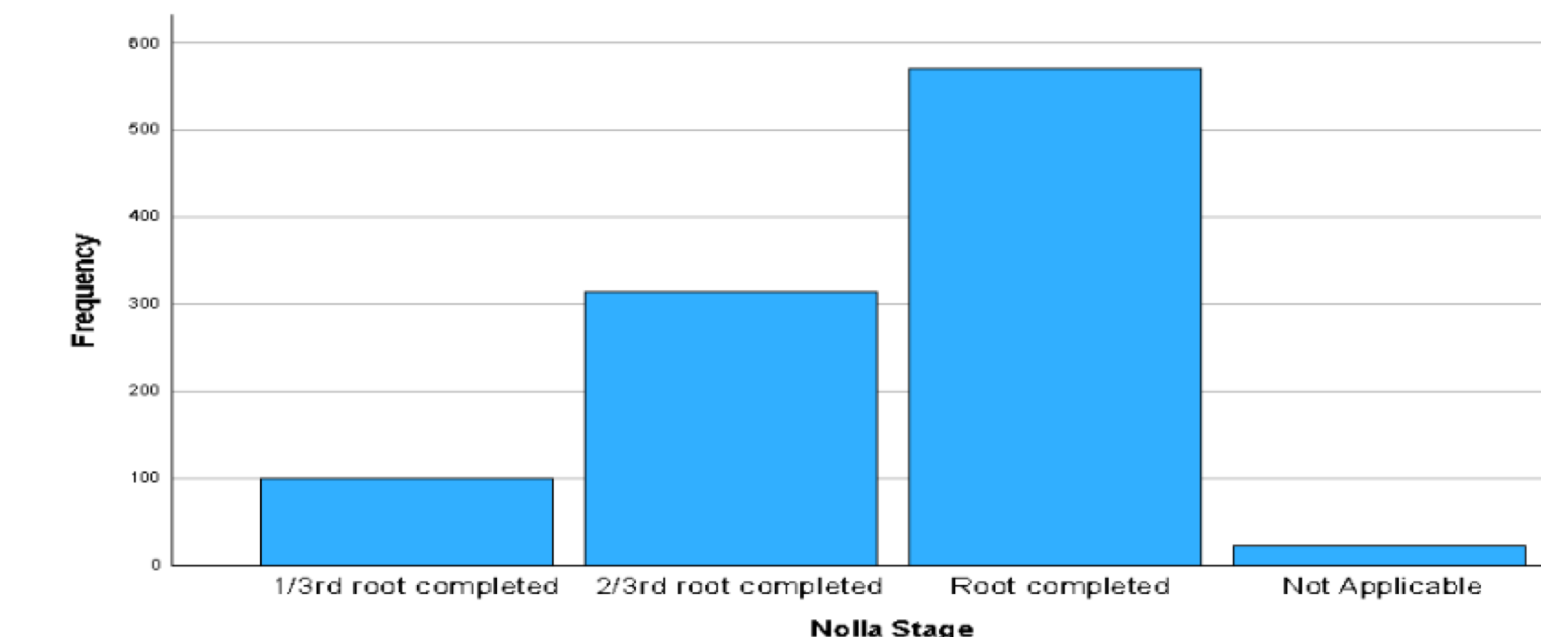


Fig. 2. Distribution of Nolla developmental stages among teeth affected by MIH.

| Variable | Category | n | % |
|---------------------------|-------------------------|----|----|
| Dental specialty | Pediatric Dentistry | 11 | 55 |
| | General Dentistry | 5 | 25 |
| | Other specialties | 4 | 20 |
| Years since graduation | < 1 year | 1 | 5 |
| | 1-5 years | 7 | 35 |
| | 6-10 years | 4 | 20 |
| | > 10 years | 8 | 40 |
| Knowledge of MIH | Yes | 19 | 95 |
| | No | 1 | 5 |
| Diagnoses MIH in practice | Yes | 14 | 70 |
| | No | 6 | 30 |
| Diagnostic method | Clinical only | 8 | 40 |
| | Clinical + radiographic | 7 | 35 |
| | Does not diagnose MIH | 5 | 25 |

Table 2. Characteristics of dental professionals participating in Study 2.

| Comparison | Chi-square df | p-value* |
|---------------------------------------|---------------|------------------|
| Specialty × Years since graduation | 10.435 (6) | 0.107 |
| Specialty × Knowledge of MIH | 3.158 (2) | 0.206 |
| Specialty × MIH diagnosis in practice | 10.714 (2) | 0.005 |
| Specialty × Diagnostic method | 8.286 (4) | 0.082 |
| Experience × Knowledge of MIH | 4.211 (3) | 0.24 |
| Experience × Diagnostic method | 6.811 (6) | 0.339 |
| Knowledge × MIH diagnosis | 2.456 (1) | 0.117 |
| MIH diagnosis × Diagnostic method | 15.833 (2) | <0.001 |

MIH: Molar incisor hypomineralization. *Asymptotic Significance

Bold = statistically significant at p < .05

Table 3. Associations between professional characteristics and MIH diagnostic practices.

Although pediatric dentists demonstrated higher positive predictive value (PPV) (53.07% vs. 42.73%) and specificity (94.03% vs. 91.72%) than general practitioners, these differences **did not reach statistical significance**

| Metric | Pediatric Dentists (Mean %) | GP/Other (Mean %) | p-value |
|-----------------|-----------------------------|-------------------|---------|
| Total agreement | 76.12 | 72.61 | 0.0346 |
| Sensitivity | 20.97 | 13.8 | 0.0439 |
| NPV | 78.58 | 76.66 | 0.0185 |
| PPV | 53.07 | 42.73 | 0.0682 |
| Specificity | 94.03 | 91.72 | 0.4031 |

NPV: Negative Predictive Value, PPV: Positive Predictive Value.

Table 4. Diagnostic performance in MIH detection among dental professionals using panoramic radiographs

CONCLUSIONS

Panoramic radiography may serve as a useful adjunctive tool for detecting moderate to severe MIH; however, it demonstrates limited sensitivity and is insufficient as a standalone diagnostic method. Although pediatric dental specialists showed modestly superior diagnostic performance, the clinical advantage was limited. Future studies should explore integrated diagnostic approaches combining radiographic assessment, clinical examination, and artificial intelligence-based tools to improve MIH detection and diagnostic accuracy.

REFERENCES

