

Oral Manifestations of Langer-Giedion Syndrome (TRPS Type II): A Case Report

Staten Island University Hospital (Ambulatory Dental Clinic)

Jenna D. Zerino, DDS

INTRODUCTION

Langer-Giedion Syndrome (LGS), also known as Trichorhinophalangeal Syndrome (TRPS) Type 2, is a rare genetic disorder associated with a microdeletion of chromosome 8. It is characterized by skeletal abnormalities (including exostoses), short statures, intellectual disability, and distinctive craniofacial features. Aside from these variations in physical traits, patients with LGS also suffer from multiple dental implications which complicate the management of their oral health. Oftentimes, LGS patients have poorer quality of mineralized dental tissues resulting in less acid-resistant enamel and dentinal structures.

CASE DESCRIPTION

This case reviews the findings of a 4-year-old male Hispanic patient who presented to SIUH Dental for a comprehensive exam. Clinical and radiographic exams were performed and revealed extensive dental caries throughout all four quadrants. Upon evaluation of the patient's medical history, his mother reported that he was diagnosed with Langer Giedion Syndrome shortly after birth. She further reports that the patient was seen by an orthopedic surgeon approximately 6 months ago for the removal of several bony exostoses. It was determined that the patient can benefit from Complete Oral Rehabilitation under General Anesthesia given the extent of treatment needed and limited cooperation level of the patient. Medical clearances were requested from patient's pediatrician and orthopedic surgeon to confirm medical optimization prior to treatment under general anesthesia.

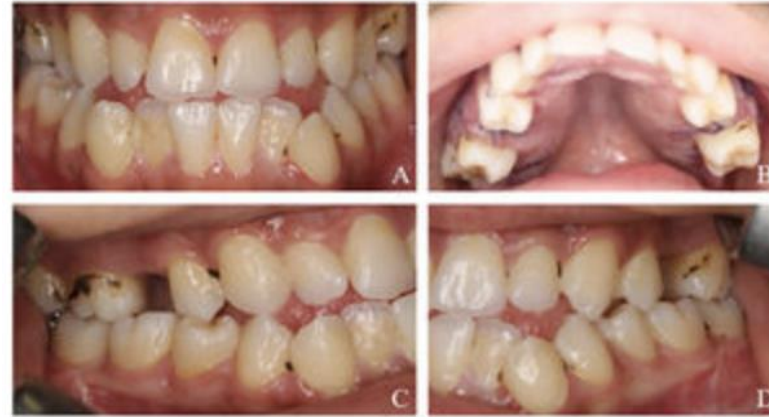

Figure 1: Clinical photos of LGS patient reveals malocclusion, retained primary teeth and generalized dental caries (Avag et al., 2023)

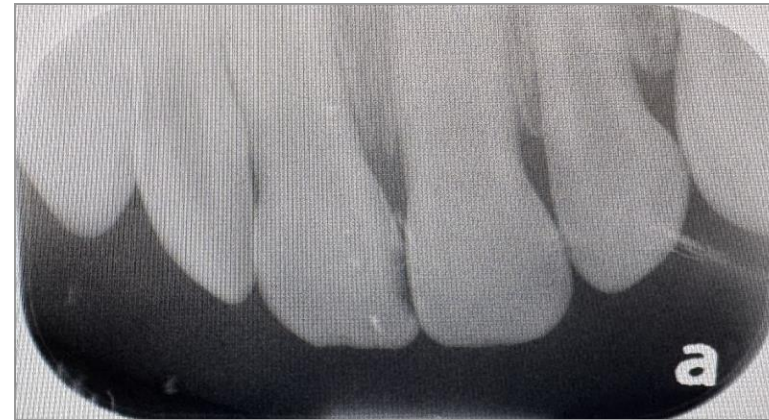


Figure 2: Anterior occlusal xray reveals dental caries on primary teeth #E and #F. Not pictured, early decalcification lesions at the cervical regions of all anterior teeth, revealing early stages of demineralization.

DISCUSSION AND CONCLUSION

There are several oral manifestations that are typically characteristic of LGS including a high caries index and microdontia, both of which were present in this particular patient. Studies suggest that the TRPS1 gene, which is affected in LGS, regulates the dental mineralization process. More specifically, mutations in the TRPS1 gene impact the expression of odontoblasts and several mineralization-related genes. Therefore, mutations in this gene have been directly correlated with reduced enamel density, decreased dentinal volume and increased rates of tooth decay. Forms of enamel hypoplasia have also been noted in cases of LGS often leading to increased susceptibility to dental caries. It is important to note that patients with LGS should be managed by a multidisciplinary team encompassing both medical and dental perspectives. Furthermore, patients with TRPS should be examined routinely and undergo full clinical and radiographic evaluations to optimize the outcomes of their treatment.

References

- Socorro M, Hoskere P, Roberts C, Lukashova L, Verdelis K, Beniash E and Napierala D (2022) Deficiency of Mineralization-Regulating Transcription Factor Trps1 Compromises Quality of Dental Tissues and Increases Susceptibility to Dental Caries. *Front. Dent. Med.* 3:875987. doi: 10.3389/fdmed.2022.875987.
- Avag, Canseda, Adiloglu, Selen, Murat, Akkocaoglu. Trichorhinophalangeal syndrome type 1 (Giedion Syndrome): A case report with literature review. *Reumatologia Clínica.* DOI: 10.1016/reumae.2022.08.005.
- Katge FA, Rusawat BD, Shivasharan PR, Patil DP. Langer-Giedion Syndrome: a Rare Case Report. *J Dent (Shiraz).* 2016 Sep;17(3):238-41. PMID: 27602401; PMCID: PMC5006835.