

Background

Dental caries remain one of the most prevalent diseases among children. It is estimated that around 520 million children suffer from dental caries in their primary dentition [1]. Untreated early childhood caries can lead to infection, pain, premature tooth loss, malnutrition, weight loss, sleeping issues, speech disorders, psychological and socioeconomic problems, missed school days, and decrease in overall quality of life [2]. In young children and patients with special healthcare needs, who may lack the ability to cooperate fully, a minimally invasive approach has increasingly shown effectiveness compared to conventional caries treatment [3, 4, 5]. ART is one such approach which involves removal of decayed tissue using hand instruments alone, usually without anesthesia and electrically driven equipment, followed by restoration of cavities with an adhesive material [4].

More specifically, Silver Modified Atraumatic Restorative Technique (SMART) is a non-invasive approach to treat dental caries with the use of Silver Diamine Fluoride (SDF) prior to placement of a restoration. SDF is a combination of an antimicrobial, a remineralizing agent, and a stabilizing agent that also happens to be an antiseptic [6]. A recent systematic review has suggested that the application of 38% SDF has an 81% likelihood of caries arrest in primary teeth, regardless of application regimen or duration of evaluation [6]. In SMART, the lesion, once arrested, is filled with a restorative material such as glass ionomer composite (GIC) [5]. This technique has been commonly used for patients lacking in cooperative ability for conventional cavity preparation and restoration, including those with special needs, high dental anxiety, pre-cooperative patients, as well as those experiencing hypersensitivity with molar incisor hypomineralization (MIH) [5].

Some literature suggests that both ART and SMART techniques offer effective short-term outcomes [2, 7, 8] while others suggest inconclusive outcomes regarding the success rate of SMART compared to other approaches [3, 4, 5, 6].

Objectives

The objective of this study is to characterize the failure pattern of Silver Modified Atraumatic Restorative Technique (SMART) restorations in primary teeth, specifically in treating single surface caries.

Study Design / Methods

The study was a retrospective chart review on primary teeth with SDF applications followed by RMGI restorations placed during the year 2023. The aim was to characterize the failure of SMART necessitating any further treatment. No additional patient characteristics were included in this study. All patients from the Division of Pediatric Dentistry at Montefiore Medical Center who had SMART restorations in 2023 were considered with 6-month follow-up intervals for 2 years.

A single reviewer extracted data from the electronic health record (Epic Systems) used at the four clinics at Montefiore Pediatric Dentistry clinics. Primary teeth treated with SDF followed by single-surface restorations were reviewed and documented. Follow up visits were reviewed to be categorized into 1) success and 2) failure outcomes. SDF code CDT D1354 and restoration codes D2330 (1 surface anterior) and D2391 (1 surface posterior) were used for data collection.

Results

A total of 89 unique patients were found to have received SDF followed by a restorative treatment within one month. Among the 89 patients, there were a total of 26 primary teeth (from 12 patients) that met the inclusion criteria.

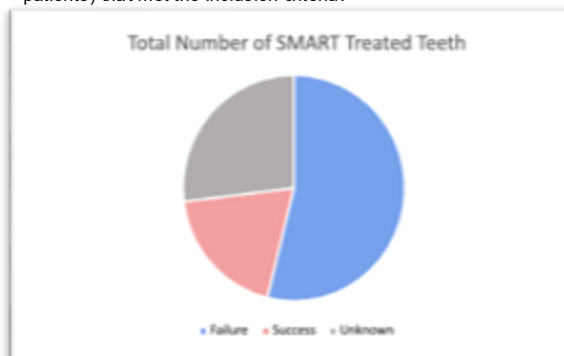


Figure 1: Total number of SMART treated teeth

Descriptive statistics were used to evaluate the clinical outcomes of SMART restorations in primary teeth treated for single-surface caries. Frequencies and percentages were calculated for restoration success, failure, and loss to follow-up. Failure timing was analyzed according to follow-up interval. Of 26 SMART restorations evaluated, 14 restorations (53.8%) failed, 5 restorations (19.2%) remained successful, and 7 teeth (26.9%) were lost to follow-up. Failures occurred most frequently at 6 months and 20 months, each accounting for 28.6% of all failures.

Results

Among the failure cases that needed retreatment after SMART restoration, 5 teeth had failed in less than 6 months, 3 teeth, in addition to the previous 5, had failed in less than 12 months, 2 additional teeth within 18 months, and 4 additional teeth within 24 months [Fig 2]. In the success cases, a total of 5 teeth had shown intact restoration with no need for retreatment [Fig 3].



Figure 2: Number of SMART failure cases in <6 mo, <12 mo, <18 mo, and <24 mo intervals from the 14 total failure cases. Number of teeth are shown to be 5 teeth within 6 months, 8 within 12 months, 10 within 18 months, and 14 within 24 months.

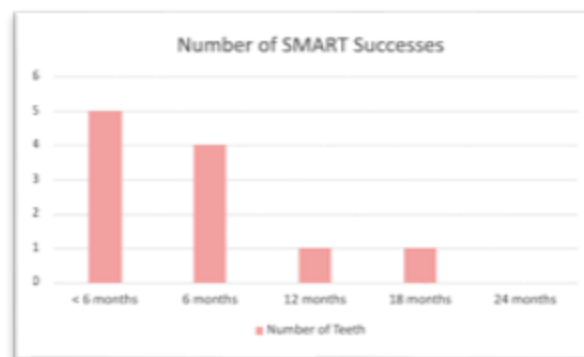

Figure 3: Number of SMART success cases in <6 mo, after 6 mo, 12 mo, 18 mo, and 24 mo from the 5 total success cases. Number of teeth are shown to be 5 teeth when followed less than 6 months, 4 teeth after 6 months, and 1 tooth after 12 and 18 months.

In summary, 14 restorations failed over the observation period, with a mean failure time of 11.9 ± 6.3 months (median: 11 months; range: 2–20 months). Failures occurred most frequently at 6 and 20 months.

Discussion/Conclusion

This study aimed to characterize the failure patterns of Silver Modified Atraumatic Restorative Technique (SMART) restorations in primary teeth, with a focus on single-surface caries. As seen by the results, the majority of SMART-treated primary teeth experienced failure with the need for retreatment, while a smaller proportion remained successful, and a notable number were lost to follow-up.

It is important to note that there were many limitations to this study. Some notable limitations are as follows:

- Some restorations may have been placed on teeth previously treated with SDF beyond the defined timeframe (> 1 month), and thus may not meet the specific SMART criteria of this study
- A substantial proportion of patients were lost to follow-up after treatment
- The sample size was smaller than anticipated, potentially limiting generalizability

Within the limitations of this study, SMART restorations in primary teeth demonstrated a relatively high failure rate over a 2-year follow up period, with failures occurring at variable time points. While a small proportion of cases were successful, the substantial number of failures and loss to follow-up limit definitive conclusions. Further studies with larger sample sizes, standardized SMART protocols, and improved follow-up are needed to better evaluate the long-term effectiveness of this technique.

References

1. Aly AAM, Aziz AMA, Elghazawy RK, El Fadl RKA. Survival Analysis and Cost Effectiveness of Silver Modified Atraumatic Restorative Treatment (SMART) and ART Occlusal Restorations in Primary Molars: a randomized controlled trial. *Journal of Dentistry*. 2023; 128:104379. doi:<https://doi.org/10.1016/j.jdent.2022.104379>
2. Bagis EE, Dereioğlu SS, Sengül F, Yılmaz S. The Effect of the Treatment of Severe Early Childhood Caries on Growth-Development and Quality of Life. *Children*. 2023; 10(2):411. doi:<https://doi.org/10.3390/children10020411>
3. Jiang M, Mei ML, Wong MCM, Chu CH, Lo ECM. Effect of silver diamine fluoride solution application on the bond strength of dentine to adhesives and to glass ionomer cements: a systematic review. *BMC Oral Health*. 2020; 20(1). doi:<https://doi.org/10.1186/s12903-020-1030-z>
4. Dorri M, Martinez-Zapata MJ, Walsh T, Marinho VC, Sheiham deceased A, Zaror C. Atraumatic restorative treatment versus conventional restorative treatment for managing dental caries. *Cochrane Database of Systematic Reviews*. 2017; (12). doi:<https://doi.org/10.1002/14651858.cd008072.pub2>
5. Hegde D, Baranya Shrikishna Suprabha, Rao A. Silver modified atraumatic restorative treatment: a paradigm shift in dental caries management. *Primary Dental Journal*. 2024; 13(2): 29-35. doi:<https://doi.org/10.1177/20501684241249545>
6. Horst JA. Silver Fluoride as a Treatment for Dental Caries. *Advances in Dental Research*. 2018; 29(1): 135-140. doi:<https://doi.org/10.1177/0022034517743750>
7. Ballkaya E, Ünverdi GE, Cehreli ZC. Management of initial carious lesions of hypomineralized molars (MIH) with silver diamine fluoride or silver-modified atraumatic restorative treatment (SMART): 1-year results of a prospective, randomized clinical trial. *Clinical Oral Investigations*. Published online November 6, 2021. doi:<https://doi.org/10.1007/s00784-021-04236-5>
8. Natarajan D. Silver Modified Atraumatic Restorative Technique: A Way Towards "SMART" Pediatric Dentistry During the COVID-19 Pandemic. *Frontiers in Dentistry*. Published online April 17, 2022. doi:<https://doi.org/10.18502/rid.v19i12.9215>