

# Interdisciplinary Management of Dental Trauma in the Mixed Dentition Patient

Noah Utesch, Michael Melugin, Gabrielle DiGiallonardo, Jennifer Bergstrom

## Background


Traumatic dental injuries (TDIs) are common in children and adolescents, with permanent incisors most frequently affected. Appropriate diagnosis and management are critical to optimize outcomes, particularly in the mixed dentition where growth, root development and eruption patterns must be considered.

Avulsion is a true dental emergency and immediate reimplantation is typically indicated as prognosis is strongly tied to extraoral dry time and storage conditions. However, reimplantation decisions must also account for tooth specific and developmental factors.

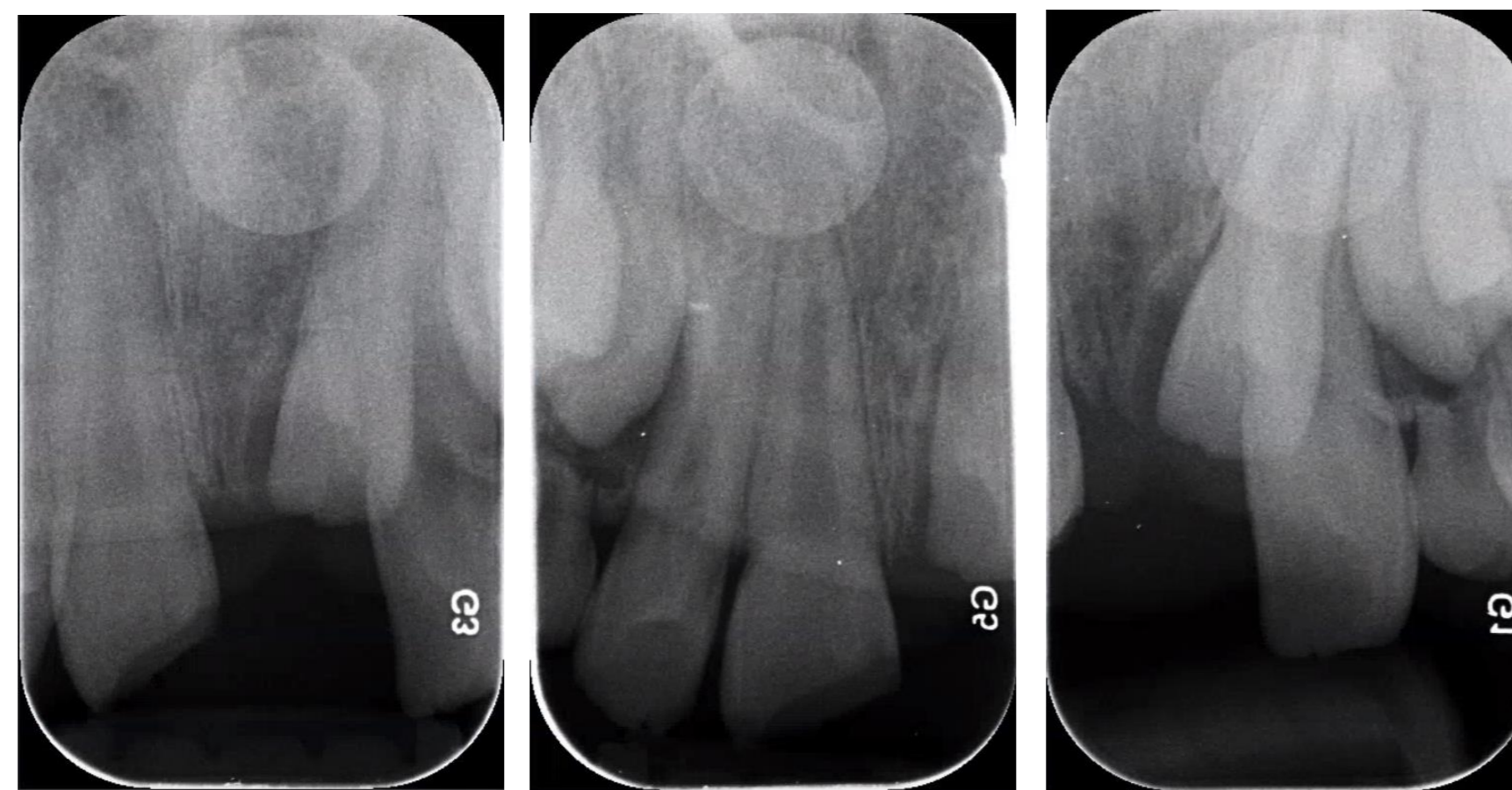
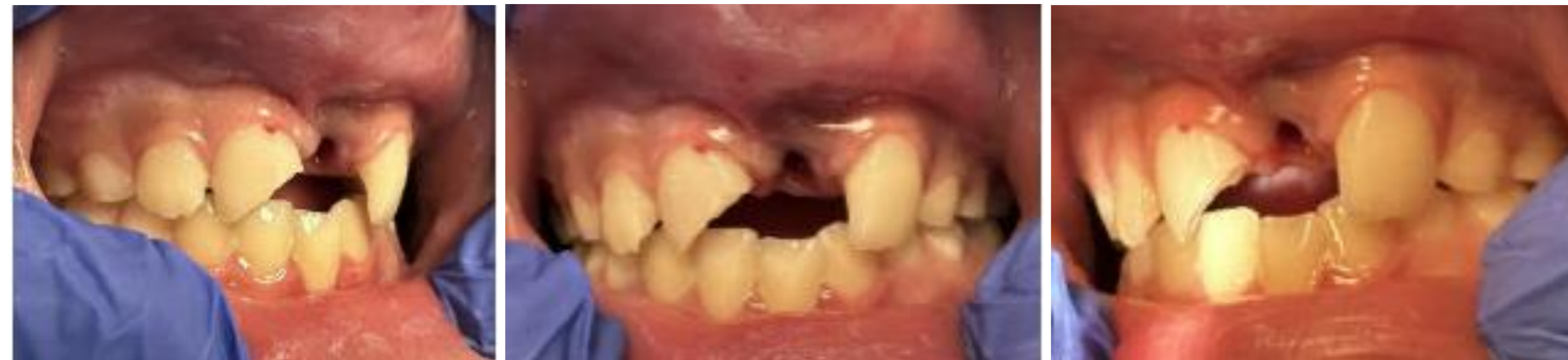Supernumerary teeth occur in 2.6% of patients and are a common cause of eruption disturbance. They may result in displacement, ectopic eruption or impaction of adjacent permanent teeth. Successful treatment of anterior supernumerary teeth often requires interdisciplinary management.

In the setting of trauma, failure to recognize preexisting developmental anomalies like supernumerary teeth may lead to inappropriate interventions and compromise overall treatment outcomes.

## Pre-Trauma Photo



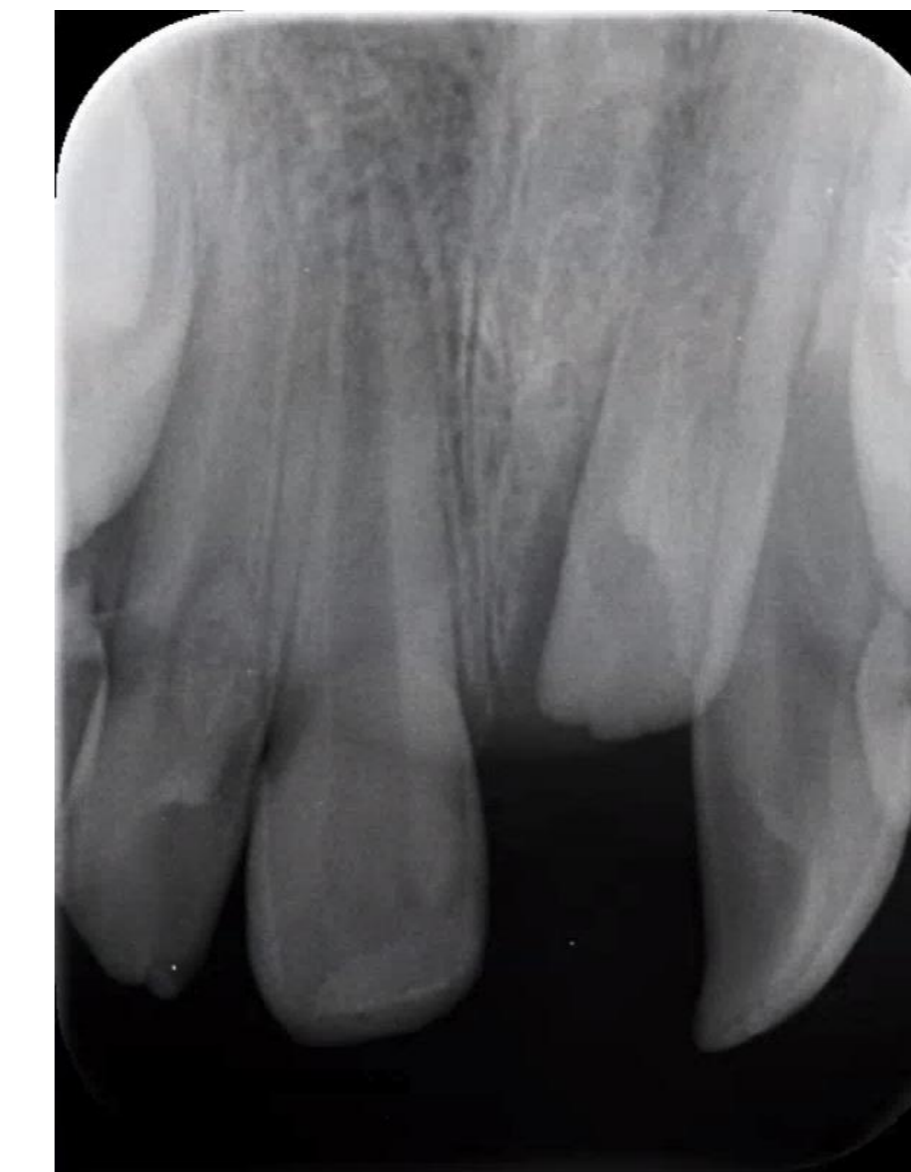## Day of Trauma



### Findings:

- Tooth #8: uncomplicated enamel-dentin fracture
- Avulsed tooth identified as #S9m
- Distal ectopic eruption of #9
- Unerupted tooth #10 palatally positioned and palpable

## Follow-up



- #8 indirect pulp cap and interim restoration are intact and stable
- Avulsion site healing well

## Case Report

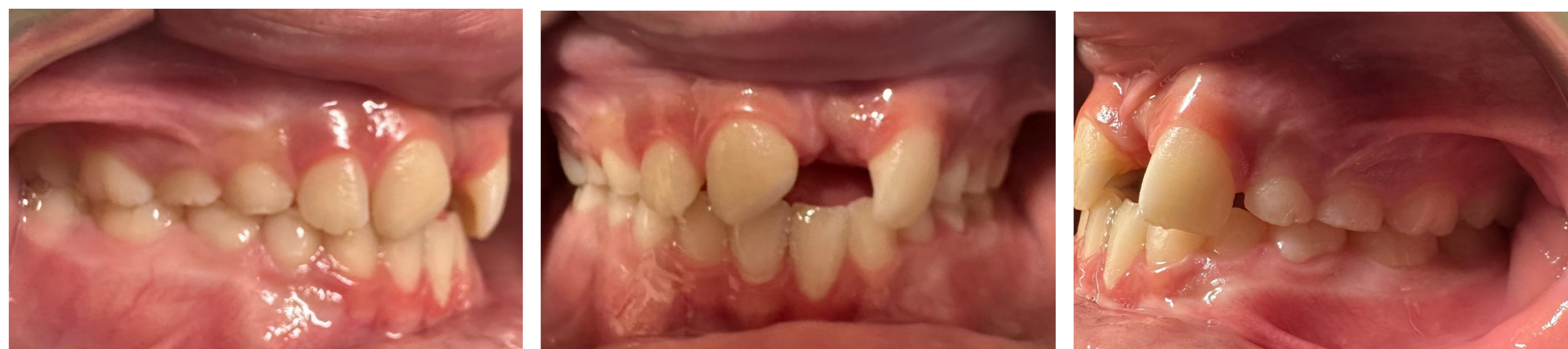A 9-year-old healthy male presented following a fall at school resulting in dental trauma. Clinical examination revealed an avulsed maxillary anterior tooth and an uncomplicated enamel-dentin fracture of tooth #8, along with minor soft tissue injuries. There was no loss of consciousness or systemic involvement.

The avulsed tooth had an extraoral dry time of less than 60 minutes and was stored in Hank's Balanced Salt Solution, conditions that would typically support reimplantation under current guidelines. However, after further evaluation, including clinical examination, radiographs and parental photographs, we identified the avulsed tooth to be an erupted supernumerary (#S9m) located between #8 and 9.

#S9m contributed to distal ectopic eruption of #9 and impaction of #10. Given its non-functional role and contribution to eruption disturbance, reimplantation was not indicated.

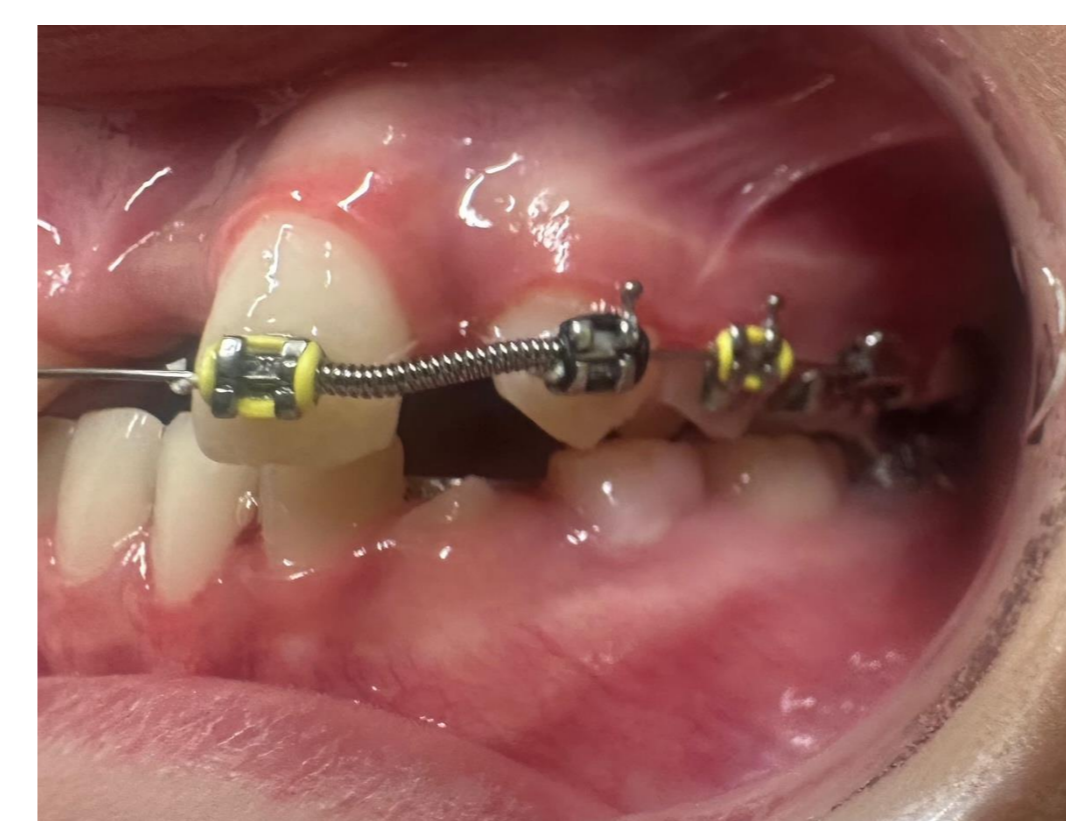
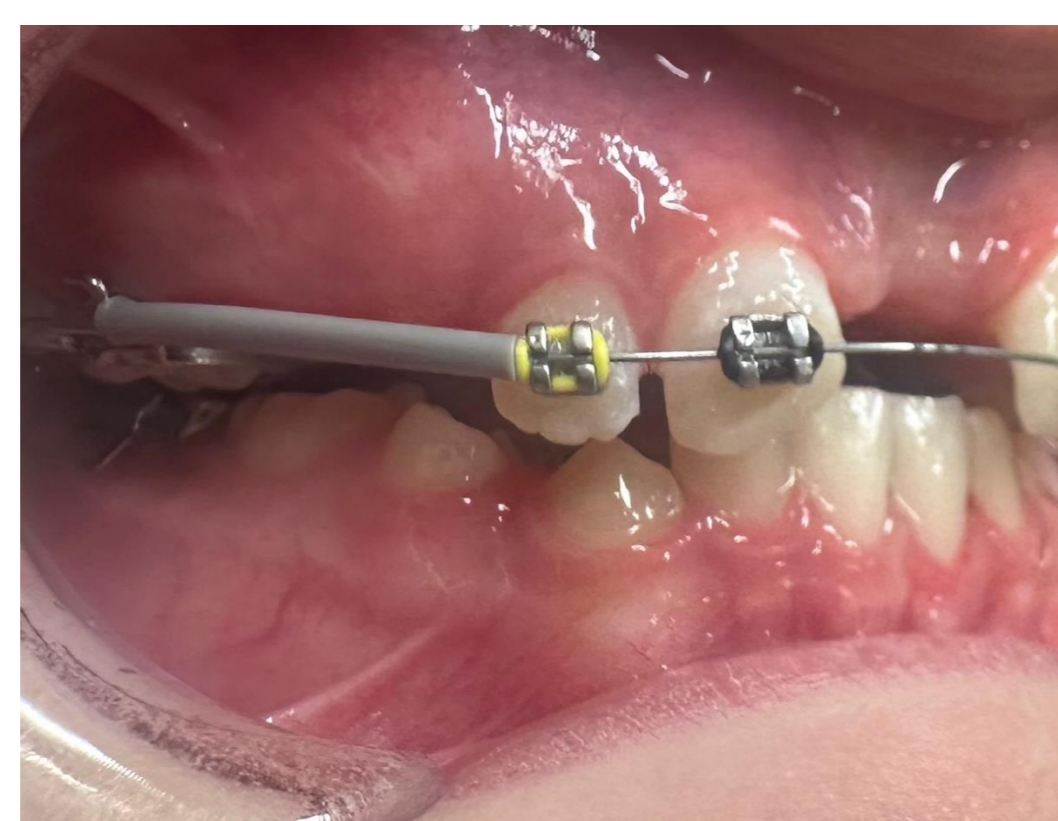
Acute management included indirect pulp capping and interim restoration of tooth #8. Phase I orthodontic treatment was initiated in October of 2025 and surgical exposure with guided eruption of tooth #10 was planned following oral surgery evaluation in March of 2026.

## Orthodontic Records and Treatment

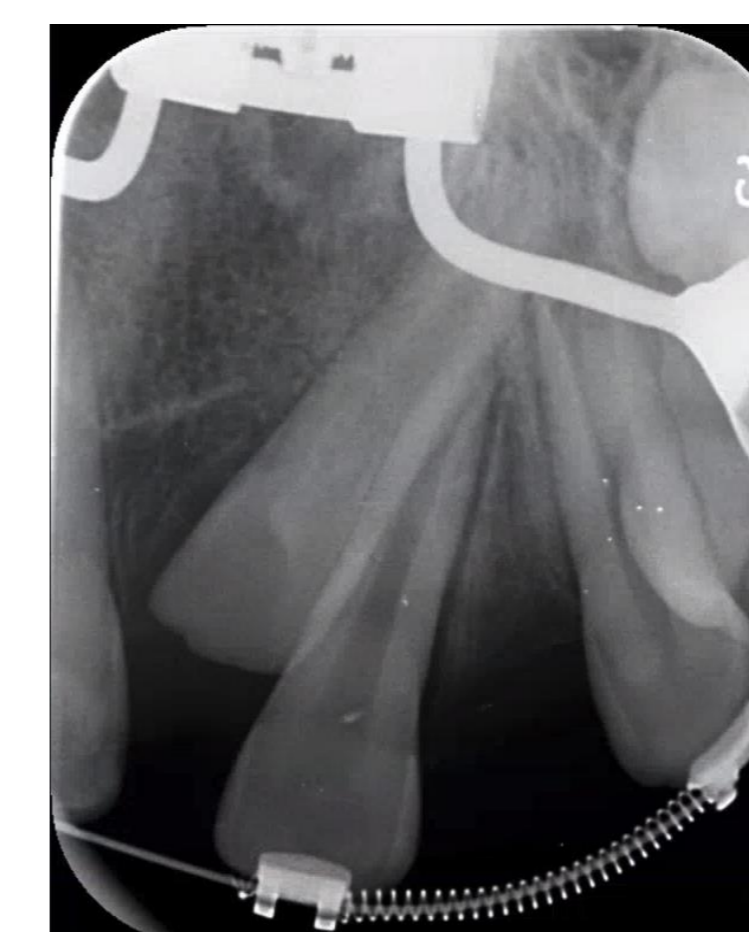

### Orthodontic Treatment Plan:

- RME/Arnold expanders
- Consolidate space U1-1
- Open space at UL2
- Surgical uncovering and guided eruption UL2



## Surgical Planning



- Apical extent of tooth #10 is appropriately positioned between teeth #9 and 11

## Conclusion

Comprehensive dental trauma assessment in the mixed dentition must include evaluation of teeth pending eruption in the involved field, with specific attention to the presence of supernumerary or congenitally absent teeth or other eruption abnormalities that might impact reimplantation, stabilization, or other procedure planning.

Identification of supernumerary teeth at the time of injury can significantly alter management decisions and improve long-term outcomes through coordinated interdisciplinary care.

## References

- Seehra J, Mortaja K, Wazwaz F, Papageorgiou SN, Newton JT, Cobourne MT. Interventions to facilitate the successful eruption of impacted maxillary incisor teeth due to the presence of a supernumerary: A systematic review and meta-analysis. *Am J Orthod Dentofacial Orthop.* 2023 May;163(5):594-608. doi: 10.1016/j.ajodo.2023.01.004. Epub 2023 Mar 11. PMID: 36907703.
- Fouad AF, Abbott PV, Tsilingaridis G, Cohenca N, Lauridsen E, Bourguignon C, O'Connell A, Flores MT, Day PF, Hicks L, Andreasen JO, Cehreli ZC, Harlamb S, Kahler B, Oginni A, Semper M, Levin L. International Association of Dental Traumatology guidelines for the management of traumatic dental injuries: 2. Avulsion of permanent teeth. *Dent Traumatol.* 2020 Aug;36(4):331-342. doi: 10.1111/edt.12573. Epub 2020 Jun 13. PMID: 32460393.