

Internal Resorption of Primary Teeth: A Potential Indicator of Systemic Disease

Alison Loper, DMD, Giovana Anovazzi, DDS, MSc, PhD
University of Michigan School of Dentistry

BACKGROUND

Lupus Erythematosus:

- Collagen vascular / connective tissue disease
- Very difficult to diagnose in its early stages
- Nonspecific, vague presentation, with periods of remission
- Women are affected 8-10 times more frequently than men
- Average age of diagnosis: 31 years of age
- Common findings: fever, weight loss, arthritis, fatigue, general malaise
- Butterfly rash in 40-50% of patients, sensitive to sunlight
- Kidneys are affected in approximately 40-50%. Can lead to kidney failure.
- Cardiac involvement: pericarditis
- Libman-Sacks endocarditis
- Some patients have developed subacute bacterial endocarditis

Pagophagia:

- Intense craving to chew on ice
- Specific form of pica (persistent, compulsive craving and consumption of non-food items that have no significant nutritional value)
- Commonly associated with iron-deficiency anemia
- Iron supplements can stop the cravings within days or weeks
- Can also be linked to psychological stress or other nutritional deficiencies

CASE PRESENTATION

An 8 year 10 month old female presents to University of Michigan Pediatric Dentistry Clinic on October 29th, 2025 accompanied by her mother for a new patient assessment.

The patient was referred to our clinic for possible resorption on primary molars.

History of present illness: Otherwise healthy

Past medical history: No medical conditions reported

Medications: None

Allergies: None known

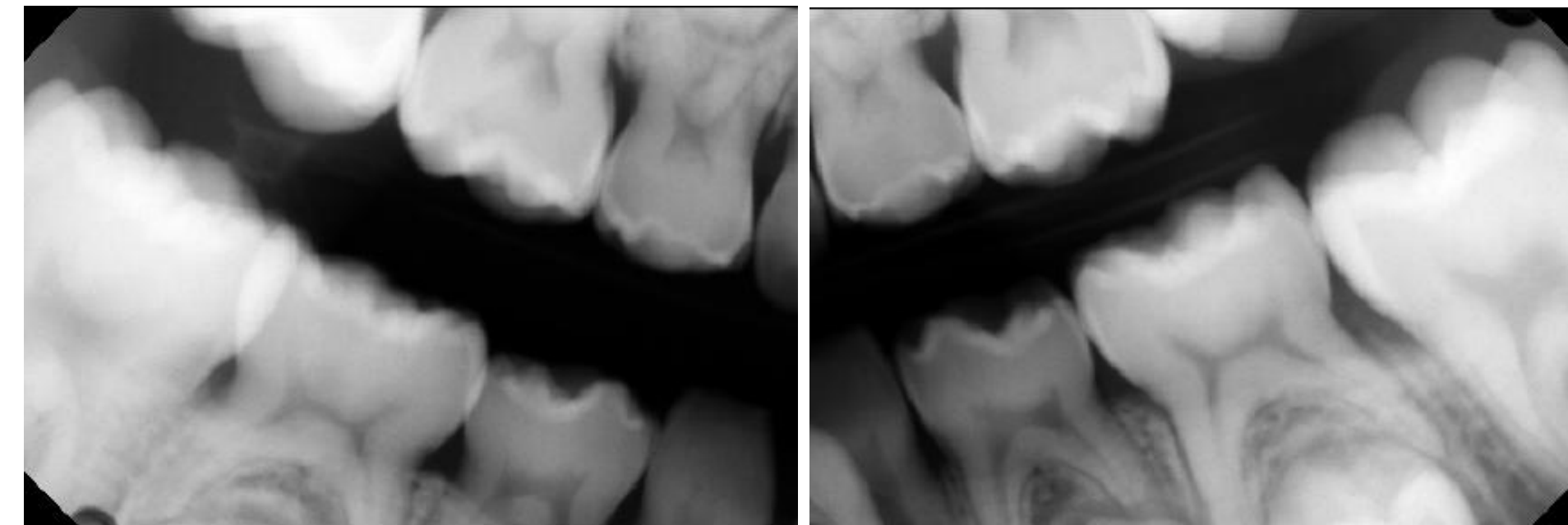
Family/social history: Lives at home with mother, father and sister

Review of systems: No significant findings

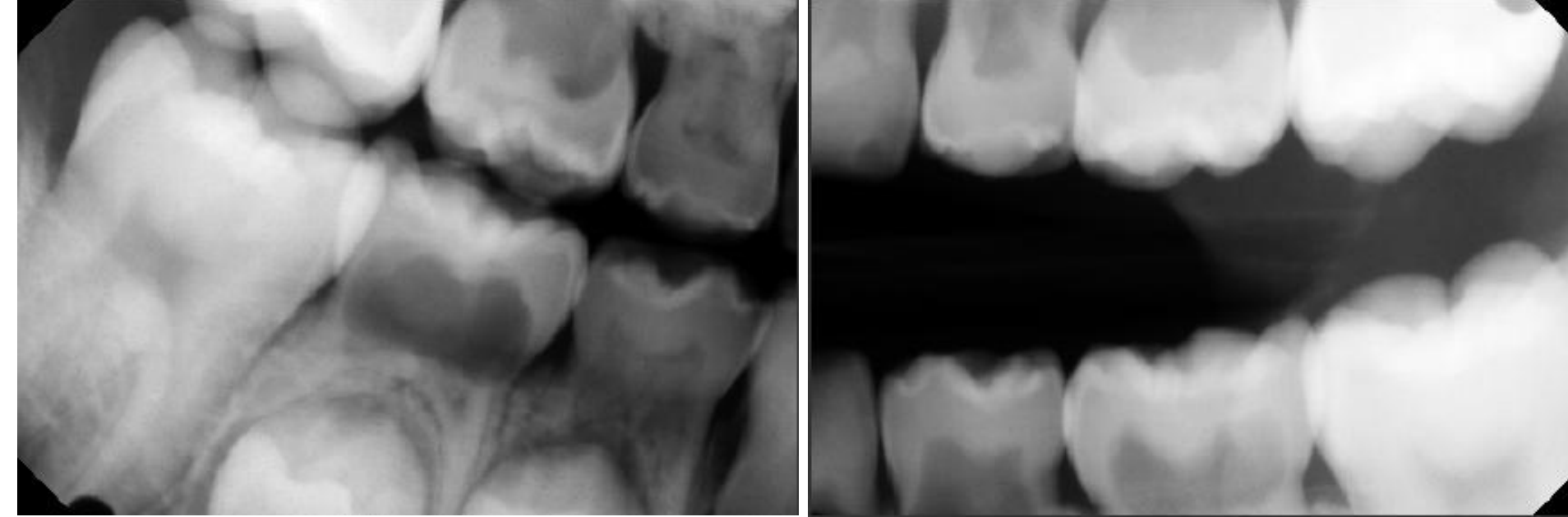
Dental history: Patient gets cleanings and checkups every 6 months at a general dentist. No history of trauma involving maxillofacial structures. No history of restorations.

Oral habits: patient regularly chews ice

August 8th, 2024: transferred from general dentist

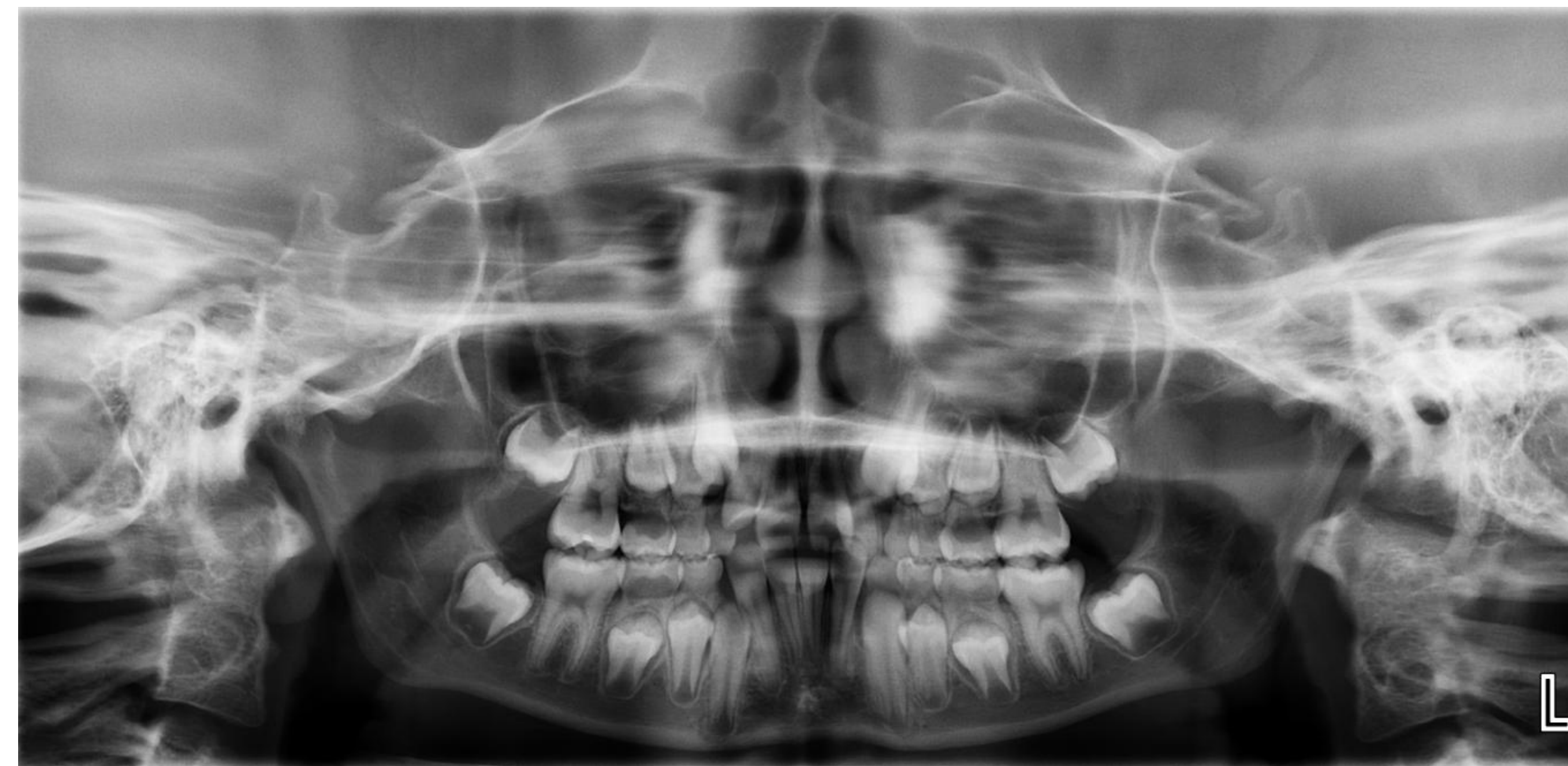

August 14th, 2025: transferred from general dentist



October 29th, 2025: Radiographic Exam

- Extensive internal resorption of teeth #A, #B, #I, #J, #K, #L, #S, #T.
- Normal appearance of surrounding structures: condyles, sinuses, etc.
- Early exfoliation of #R: space loss
- Permanent teeth do not appear to be affected at this time
- Third molars are not yet visible



Imaging and Results

October 29th clinical exam:

EOE: no pathology detected, convex profile
IOE: no soft tissue pathology detected

Dental exam:

- Mixed dentition
- Fair OH
- Canine class I R&L
- Molar class I R&L
- No clinical caries detected
- No traumatic occlusion
- No mobility
- Normal clinical appearance of teeth (color, shape)
- Severe crowding on upper and lower arches
- Overbite = 2 mm
- Overjet = 5 mm

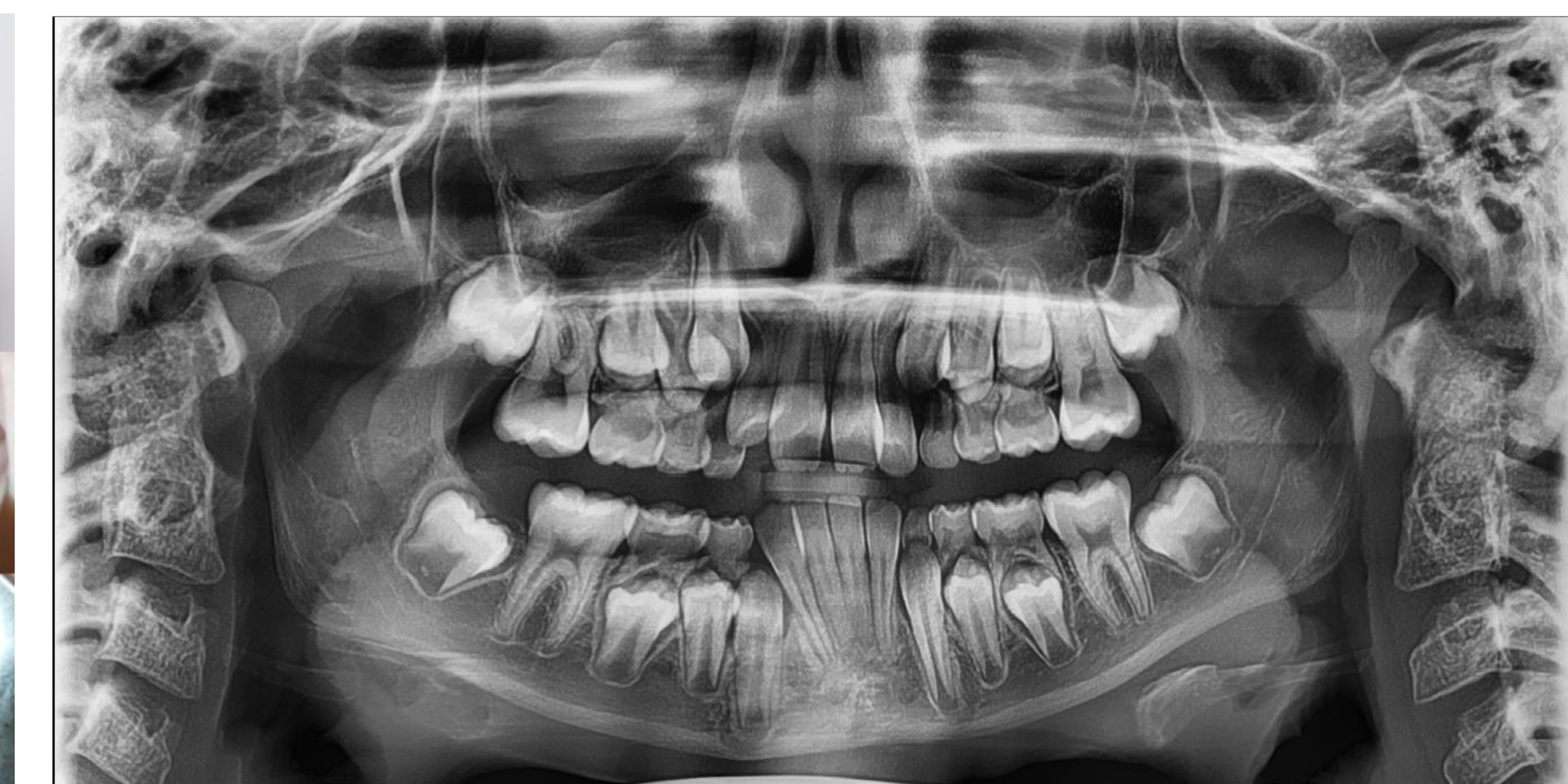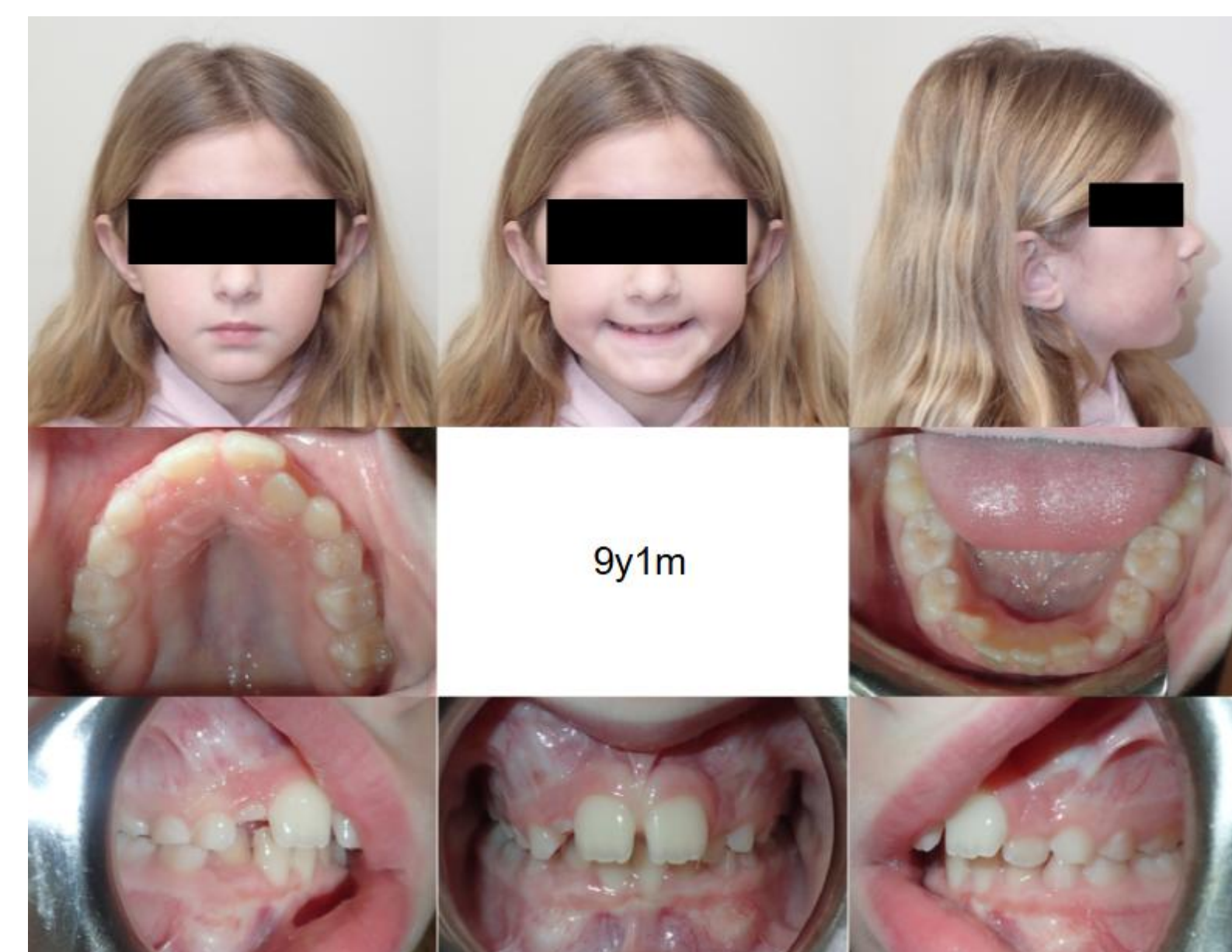Interprofessional Collaboration:

- Consult sent to patient's PCP, informing him of our concern
- Patient underwent CPP antibody test on 11/26/25
- Results were sent to our clinic by fax : ANA titer was 1:1280 (reference range is <1:80), low Ferritin

Follow-up Phone Call with Mother in March 2026:

- Patient was **diagnosed with Systemic Lupus Erythematosus** (February 2026)
- She has no history of symptoms in any system
- Current plan is to monitor for symptoms
- Patient is not starting any therapy at this time
- No changes in teeth
- Ice chewing habit was stopped immediately after the appointment
- Started palate expansion with orthodontist a few weeks ago

January 19th, 2026: Orthodontic records, clinical photos and panoramic radiograph



CLINICAL MANAGEMENT

Recommendations and Plan:

- Recommended to stop ice chewing habit
- Follow up closely with general dentist with radiographs to determine if the condition is progressing, or if permanent teeth become affected
- If a tooth fractures or exfoliates prematurely, plan for space maintenance

DISCUSSION

Key Takeaways:

- Suspect systemic conditions when a generalized pattern is observed
- Importance of interprofessional collaboration
- Importance of routine radiographs in patient care

Discussion Questions:

- Is orthodontic treatment appropriate at this time?
- Is the etiology more likely to be related to the Lupus or the pagophagia?

REFERENCES

- Neville, B.W., Damm, D.D., Allen, C.M. and Chi, A.C. (2016) Oral & Maxillofacial Pathology. 4th Edition, WB Saunders, Elsevier, Missouri, 604-605.
- Eskandari, F., Sahebi, S., Ghorbani Jahandizi, N. et al. Endodontic management of internal replacement resorption of two maxillary central incisors with the aid of cone-beam computed tomography as the diagnostic tool: a case report and review of literature. J Med Case Reports 19, 200 (2025). <https://doi.org/10.1186/s13256-025-05148-8>
- Uchida, T., & Kawati, Y. (2014). [Rinsho ketsueki] The Japanese journal of clinical hematology, 55(4), 436-439. <https://rheumforprimarycare.org/rashes/>
- Kalaoglu, E. E., & Ozturkmen, Z. (2025). Prevalence and associated factors of pathologic root resorption in primary molars and canines: a retrospective cross-sectional study. Quintessence international (Berlin, Germany : 1985), 56(6), 500-508. <https://doi.org/10.3290/j.qi.b6184182>
- Dupre, N., Riou, M. C., Isaac, J., Ferre, F., Cormier-Daire, V., Kerner, S., de La Dure-Molla, M., Nowwarote, N., Acevedo, A. C., & Fournier, B. P. J. (2024). Root resorptions induced by genetic disorders: A systematic review. Oral diseases, 30(6), 3799-3812. <https://doi.org/10.1111/odi.14942>