An Underrecognized Pitfall in Parotidectomy Facial Nerve Monitoring: Recent Botulinum Toxin Use

Emily S. Sagalow, MD[1]; Caroline Liu, MD, MHS[1]; Aniruddha Parikh, MD[1]; Robert Wang, MD[1]
[1]Department of Otolaryngology–Head & Neck Surgery, University of Nevada, Las Vegas, Las Vegas NV

Introduction

- Intraoperative facial nerve monitoring (IOFNM) is commonly used during parotidectomy to assist with nerve identification and functional assessment
- A less frequently noted of absent EMG response is botulinum toxin, which acts by presynaptically blocking acetylcholine release and producing temporary chemodenervation
- Cosmetic botulinum toxin injection is the most common minimally invasive aesthetic procedure in the United States with treatments most targeting glabellar, frontalis, and periocular musculature
- Patients are likely to have received recent botulinum toxin injections, which they may not disclose

Methods

- **Study Design:** Case report
  - 61-year-old female with a 4.7-cm left parotid pleomorphic adenoma who underwent left partial parotidectomy
  - Tertiary academic center
  - Standard four-channel intraoperative facial nerve electromyographic monitoring
- *Intraoperatively:* Stimulation responses from individual facial nerve branches
- *Postoperatively:* Facial nerve function was evaluated clinically

Results

- *Intraoperatively:*
  - Buccal and marginal mandibular branches:
    - Produced robust midface and lower lip responses of 400 to 500 µV
  - Periocular stimulation (with an electrode at the lateral canthus near the crow's feet)
    - Elicited ***markedly weaker responses of only 103 to 126 µV***
  - Temporal branch stimulation (with an electrode placed in the forehead)
    - Never generated a measurable response ***despite repeated stimulation and confirmed nerve continuity on direct visualization***
- These findings prompted intraoperative discussion with the patient's family
  - Disclosed cosmetic botulinum toxin injections to the frontalis, orbicular oculi, procerus, and corrugators two months prior to surgery

Figure 1: Intraoperative Facial Nerve Monitoring: The Botulinum Toxin Adjustment Guide

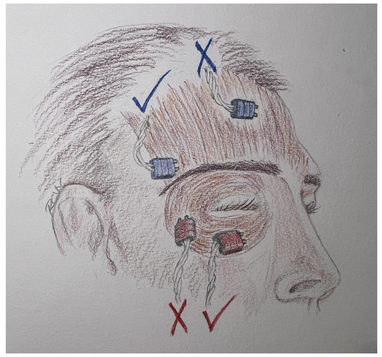

Figure 1 demonstrates suggested electrode placement in patients with known or suspected preoperative botulinum toxin treatment to the upper face to allow for greater reliance on distal branch stimulation, direct nerve visualization, and electrodes over less affected muscle regions may provide more reliable information.

Discussion & Conclusion

- Recent cosmetic botulinum toxin injections may reduce the reliability of periocular and temporal facial nerve monitoring during parotidectomy without indicating true nerve dysfunction
- This limitation may also extend to facial nerve monitoring in otologic and lateral skull base procedures that rely on periocular or facial muscle electromyography
- When recent botulinum toxin exposure is suspected or confirmed, surgeons should anticipate attenuated signals and interpret monitoring data with caution
- Consideration may be given to adjusting electrode placement to target less affected muscle groups, emphasizing direct nerve visualization and stimulation of distal branches, rather than reliance on periocular leads alone
- Routine preoperative inquiry regarding recent botulinum toxin use may improve intraoperative decision-making and prevent misinterpretation of nerve monitoring results

References

1. Meier JD, Wenig BL, Manders EC, Nenonene EK. Continuous intraoperative facial nerve monitoring in predicting postoperative injury during parotidectomy. Laryngoscope. 2006;116(9):1569-1572. doi:10.1097/01.mlg.0000231266.84401.55
2. Ahn D, Kwak JH, Kim GJ, Kim H, Lee DW, Cho KJ. Intraoperative Facial Nerve Monitoring during Parotidectomy: The Current Practices and Patterns of the Korean Society of Head and Neck Surgery (KSHNS). Diagnostics (Basel). 2024;14(20):2277. Published 2024 Oct 13. doi:10.3390/diagnostics14202277
3. American Society of Plastic Surgeons. 2024 Plastic Surgery Statistics Report. Published 2025. Accessed July 10, 2026. https://www.plasticsurgery.org/documents/news/statistics/2024/plastic-surgery-statistics-report-2024.pdf
4. Habeych ME, Shah AC, Nikonow TN, et al. Effect of botulinum neurotoxin treatment in the lateral spread monitoring of microvascular decompression for hemifacial spasm. Muscle Nerve. 2011;44(4):518-524. doi:10.1002/mus.22104
5. Wang L, Azizzadeh B. Technical considerations for modified selective neurectomy in the management of post-facial paralysis with synkinesis. Operative Techniques in Otolaryngology-Head and Neck Surgery. 2022;33(1):41-44. doi:10.1016/j.otot.2022.02.007